



CASE REPORT

A Case of Uterine Arteriovenous Malformation with Retained Products of Conception, Presenting as Secondary Post-Partum Haemorrhage

OG Abutu¹, Bivas Biswas^{2*}, Onnig Tamizian² and AS Tirlapur²



¹Specialty Registrar in Obstetrics and Gynaecology, Department of Obstetrics and Gynaecology, Royal Derby Hospital, University Hospitals of Derby and Burton NHSFT, United Kingdom

²Consultant in Obstetrics and Gynaecology, Department of Obstetrics and Gynaecology, Royal Derby Hospital, University Hospitals of Derby and Burton NHSFT, United Kingdom

*Corresponding author: Bivas Biswas, Consultant in Obstetrics and Gynaecology, Department of Obstetrics and Gynaecology, Royal Derby Hospital, University Hospitals of Derby and Burton NHSFT, DE22 3NE, United Kingdom

Abstract

Uterine arteriovenous malformation (AVM) is defined as the rare occurrence of an abnormal and nonfunctional connection between uterine arteries and veins. Bleeding per vaginum is the typical presentation with potential for acute onset, life threatening haemorrhage. Investigations including ultrasound with or without doppler, magnetic resonance imaging [MRI] and angiography are often used to aid in the diagnosis. Management of uterine AVMs depend on the hemodynamic status of the patient, size and site of the lesion, severity of bleeding symptoms, age of the patient, desire for future fertility and treatment expertise available at hand.

The therapeutic options available include medications like uterotonic and the combined contraceptive pill, balloon tamponade, surgical removal of the AVM, laparoscopic bipolar coagulation, uterine artery embolization and hysterectomy. The case we report is of a 27-year-old primigravida with acute onset vaginal bleeding, 3 weeks post ventouse delivery. She was resuscitated and investigated and subsequently had uterine artery embolization, prior to having a surgical evacuation of retained products of conception.

intervening capillary vessels [2,3]. Uterine AVMs are a rare entity, classified into either congenital or acquired. Congenital uterine AVMs are thought to develop from a defect during embryologic differentiation leading to abnormal vascular connections, whereas acquired uterine AVMs have been reported to occur secondary to previous uterine trauma, such as a curettage or a caesarean delivery, or be associated with neoplastic disorders, including gestational trophoblastic disease (GTD) and endometrial adenocarcinoma [1,2].

Although uterine AVMs are uncommon, they have the potential of causing irregular and occasionally massive life-threatening uterine hemorrhage, requiring blood transfusions [1]. Due to this potentially dangerous condition, prompt diagnosis and treatment of uterine AVM's is necessary in order to avert catastrophic outcomes.

Incidence

The first reported case of AVM in literature, is attributed to Dubreuil and Loubat, et al. in 1926 [2,3]. There is a paucity of information in reported literature regarding the frequency of these lesions. This is further confounded by the fact that some uterine bleeding due to these lesions respond satisfactorily to medical management, and several of these may therefore go undiagnosed, and thus not reported. The lack of a standard

Introduction

Arteriovenous malformations (AVMs) also referred to as cirroid aneurysm, arteriovenous aneurysm, arteriovenous fistula and cavernous hemangioma, can occur in any organ in the body [1]. AVMs are said to occur when there is direct connection of the arterial and the venous systems, without any contribution from usually

definition to identify true AVMs also remains a clinical challenge yet to be overcome [3]. O'Brien, et al. and Yazawa, et al., in studies involving cohorts of patients undergoing pelvic sonographic evaluations for uterine bleeding, reported variable incidences of 4.5% and 0.6% respectively [3].

Diagnosis

Diagnosis of uterine AVM could be made by using non-invasive methods like transvaginal ultrasound (TVS) and the colour doppler. The findings in TVS, however, can be non-specific and thus this investigation cannot be used to differentiate and rule out other causes of PPH like retained products and GTD [2,3]. Colour doppler helps to augment the accuracy of TVS in making the diagnosis of uterine AVM. Where available, MRI has been used to aid in the diagnosis. However, angiography is considered by many, to be the gold standard for diagnosis [2,3].

Some have argued that uterine AVMs have been over diagnosed, with the increasing use of ultrasound and colour doppler for its detection. It has been suggested that lesions detected with hyper vascular and turbulent flow be designated as 'uterine vascular malformations' and the term uterine AVM, be restricted to those lesions demonstrating a hyper vascular mass with early filling on angiography or on pathologic examination of the uterus after hysterectomy [3].

Treatment

Management of uterine AVM depends on the haemodynamic status of the patient, size and site of the lesion, degree of bleeding symptoms, age of the patient, desire for future fertility [1-3] and the availability of medical expertise. Available treatment modalities include medications like uterotonics and the combined contraceptive pill, balloon tamponade, surgical removal of AVM, laparoscopic bipolar coagulation, uterine artery embolization (unilateral or bilateral) and hysterectomy [1-4].

Case Report

A 27-year-old primigravida, had an uneventful gestation followed at term by a ventouse delivery with episiotomy, for prolonged second stage. The blood loss documented at birth was 700 milliliters and the placenta and membranes were noted to be complete. She presented to the pregnancy assessment unit, 3 weeks following birth, complaining of bleeding per vaginum, unusual and in excess of her usual lochia. At the time of this presentation, she had had secondary post-partum haemorrhage of about another 800 milliliters, and felt anxious, unwell and dizzy. Her observations were noted to be stable and a per speculum examination revealed a closed cervical with some bleeding noted, emanating from the uterine cavity. The uterine cavity was initially found to be contracted, consistent with a 3 weeks post-natal uterus. Her haemoglobin was found to be

124 gram/deciliters and her white blood cell and C-reactive protein counts were normal. She was admitted for observation and while on the ward, there was ongoing secondary post-partum haemorrhage and in-between the bleeding episodes, uterine atony was noted on internal examination.

A working differential diagnosis of uterine atony and endometritis was made and the initial management consisted of intravenous fluid resuscitation, uterotonics and broad spectrum antibiotics. A TVS was performed which revealed a mass at the fundus with separate evidence of retained products of conception in the endometrial cavity. Subsequent doppler and MRI studies confirmed uterine AVM at the uterine fundus and retained products of conception [RPOC] in the cavity. These findings were discussed with the patient and the interventional radiologist, and an angiography and concurrent uterine artery embolization, using gel foam was performed, prior to performing a surgical evacuation of the RPOC, immediately post-embolization, in theatre. Bleeding per vaginum stopped post-procedure and the patient was discharged home in 48 hours, on oral antibiotics. The final histology confirmed RPOC, with no evidence of gestational trophoblastic or endometrial neoplasia. The patient was subsequently followed up in gynaecology clinic in two months time and was doing well. Repeat USS performed at this time was normal and she was discharged with no further follow up appointments.

Discussion

Uterine AVM could present in a variety of ways, from asymptomatic to periodic or episodic vaginal bleeding or secondary post-partum haemorrhage to life threatening torrential vaginal bleeding. It is a recognised cause of primary and secondary PPH. In a review by Ya-Pei, et al. [1], in 58 bleeding patients with uterine AVM, the inciting event or procedure was miscarriage, including artificial abortion and medium induction with or without curettage in 45 (77.6%), full-term normal delivery in 3 (5.2%), caesarean section in 3 (5.2%), and GTD in 7 (12.1%) [1]. This data reflects that uterine AVM following vaginal delivery might be somewhat rare compared with other preceding or inciting events.

We did a TVS due to the atypical presentation [on-going uterine bleed with an involuted uterus and a closed cervical] in our case, which confirmed a bulky uterus containing mixed echogenous material (measuring 1.8 × 2.1 × 2.8 cm and with a volume of 5.5 mls) in the cavity. There was evidence of vascularity within the fundus on scan. On further imaging with colour doppler, there was a prominent area demonstrating turbulent hyper vascular flow, prompting a differential of AVM with RPOC. This is displayed in [Appendix 1](#).

An MRI was performed which showed soft tissue filling defect in the fundus with a serpiginous vessel extending towards it, with enhancement of this seen on the arterial phase of the dynamic tricks sequences. An impression of a fundal intra-cavity vascular abnormality was made as evident in [Appendix 2](#). She subsequently had an angiography which confirmed the AVM and uterine artery embolization using gel foam was used as enumerated in [Appendix 3](#).

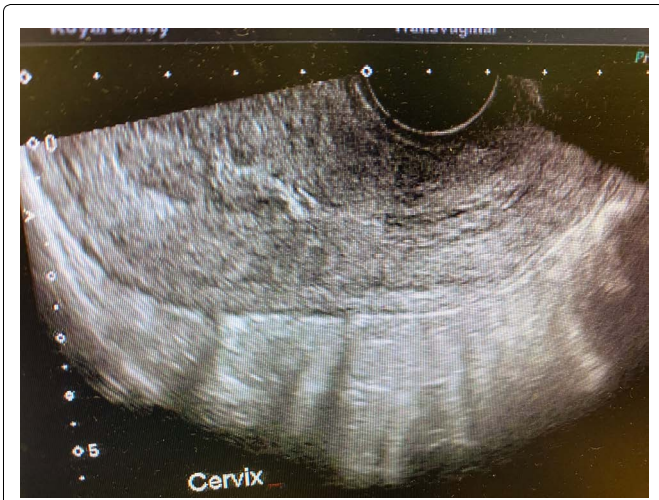The challenge posed in this case was the coexistence of uterine AVM and RPOC with the clinical conundrum of which condition to address first. As evacuation of RPOC could potentially lead to more bleeding with possibility of that being torrential, we opted for uterine artery embolization first, followed by immediate gentle evacuation in theatre, as gel foam embolization provided a rather small window of opportunity for any therapeutic procedure to be safely carried out.

In the past AVMs were difficult to diagnose, and were usually only confirmed retrospectively, in post hysterectomy specimens. However, the availability of doppler ultrasound scanning has made the diagnosis of AVM relatively more feasible [4], though confirmation

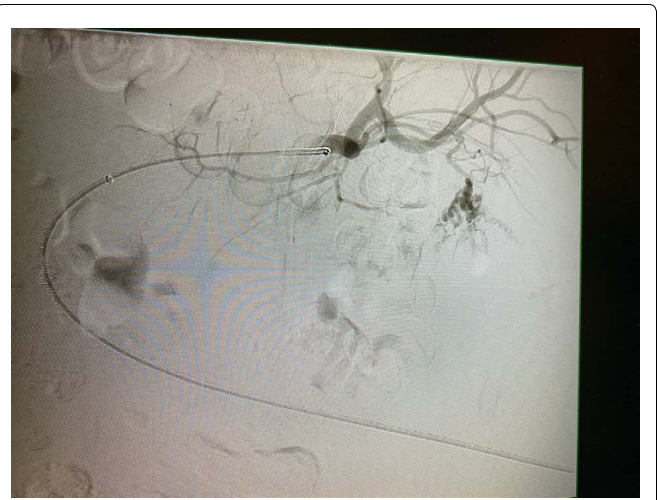
with angiography is usually required prior to intervening. Uterine artery embolization (UAE) is increasingly becoming one of the preferred treatment modalities in this setting, primarily due to its effectiveness as well as being minimally invasive in nature, with the resultant possibility of preserving uterine function to allow future childbearing [4] and the ready availability of experts to perform these procedures. Prompt resuscitation, appropriate and timely investigation, a high index of suspicion and timely treatment is essential for avoiding a catastrophic outcome in this situation.

References

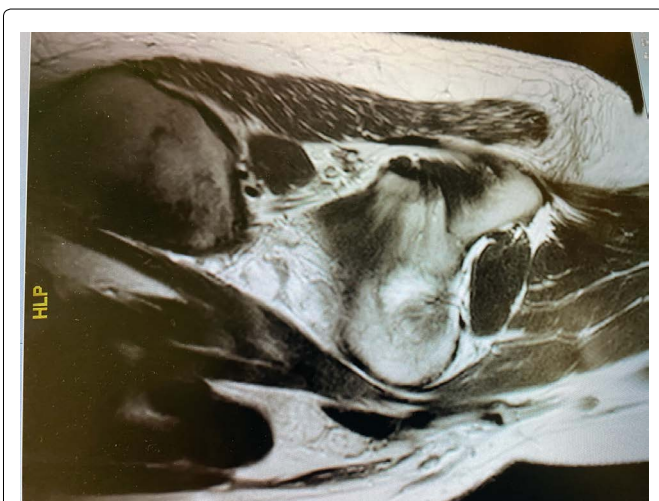
1. Ya-Pei Z, Zhi-Jing S, Jing-He L, Jie P (2018) Clinical characteristics and management of acquired uterine arteriovenous malformation. *China Med J(Engl)* 131: 2489-2491.
2. Firoozeh A, Somayeh M (2018) A case of generalised uterine arteriovenous malformation after molar pregnancy in an infertile woman. *Int J Reprod BioMed* 16: 119-122.
3. Thangamma KA, Sreejith KS (2015) Uterine arteriovenous malformation: Clinical implications. *The Obst and Gyn*.
4. Khan S, Saud S, Khan I (2019) Acquired uterine arteriovenous malformation following dilatation and curettage treated with bilateral uterine artery embolization: A case report. *Cureus*.



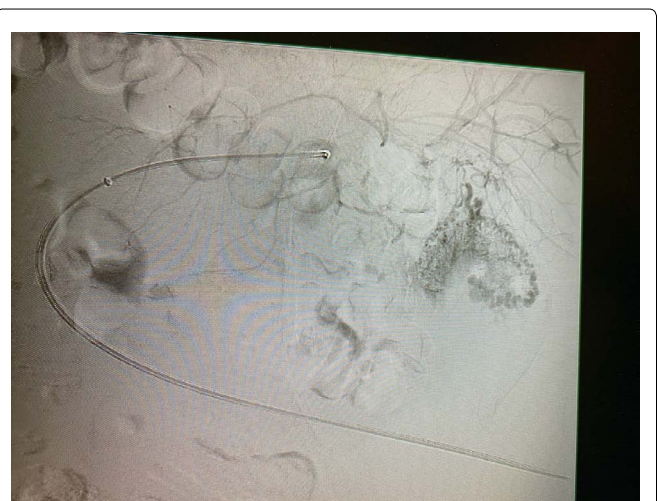Appendix 1: USS.



Appendix 3A: Angiograph.



Appendix 2: MRI.



Appendix 3B: Angiogram.