



CASE REPORT

Microsurgery for Grade III Cerebral Arteriovenous Malformations Related to the Eloquent Peri-Rolandic Territory: Case Series

Ahmed Muthana¹, Zahraa A Alsubaihawi¹, Ali Adnan Dolachee², Mustafa E Almurayati¹, Oday Atallah³, Mustafa Ismail¹ and Samer S Hoz^{4*}

¹Department of Neurosurgery, University of Baghdad, Baghdad, Iraq

²Department of Surgery, Al-Kindy College of Medicine, University of Baghdad, Baghdad, Iraq

³Department of Neurosurgery, Hannover Medical School, Carl-Neuberg-St. 1, 30625 Hannover, Germany

⁴Department of Neurosurgery, University of Cincinnati, Cincinnati, Ohio, United States

*Corresponding author: Samer S Hoz, Department of Neurosurgery, University of Cincinnati, Cincinnati, Ohio, United States



Abstract

Introduction: Spetzler-Martin grade III arteriovenous malformation (AVM) located in the peri-Rolandic area involves the motor or sensory cortex. Its management is particularly controversial and requires a multimodal approach.

Methods: From September 2018 to March 2022, we reviewed patients harboring grade III AVM located in peri-Rolandic areas that had been treated with microsurgery at the Baghdad Neurosurgery Teaching Hospital. Eighteen parameters were applied to each case, which were categorized into pre-, intra-, and postoperative factors.

Results: A total of 8 Patients are included in this study. The size of the AVM was between 35 mm and 54 mm. Sensory-located AVM was found in 5 cases, and the remaining 3 cases have motor-located AVMs. Total removal of AVM was achieved in 7 cases. 6 patients developed new neurological deficits after surgeries which were resolved in subsequent weeks and the mRS score at follow-up was 1 in all patients.

Conclusion: Microsurgical management of peri-Rolandic Spetzler-Martin grade 3 AVM is challenging; however, it is still more promising in achieving full excision of the lesion.

Keywords

Grade III arteriovenous malformation, Spetzler-Martin grading system, Peri-Rolandic area, Eloquent, Microsurgery, Radiosurgery, Embolization

Abbreviations

AVM: Arteriovenous Malformation; CT: Computed Tomography; GCS: Glasgow Coma Scale; mRS: modified Rank in scale

Introduction

In 1986, Spetzler and Martin published what has become the predominant classification scheme for brain AVMs [1]. This scheme classifies the AVM into five grades to provide a good stratification regarding morbidity and mortality following the management of AVMs. Of all grades, grade III AVM with eloquence involvement is still a dilemma, and its management is particularly controversial and requires a multimodality approach [2,3]. Many authors support radiosurgical management since it is more appealing and essentially devoid of immediate treatment-related complications [4], while others go with endovascular management, which expands the ability to treat a wider range of AVMs [5].

The microsurgical management of grade III AVMs has been declining in the last few decades, especially after the introduction of minimally invasive procedures. In special cases, where the lesion involves peri-Rolandic areas, Safe microsurgical resection can be challenging, however, promising [6]. In our study, we describe our experience with eight cases harboring an AVM in the peri-Rolandic area which underwent microsurgical resection. We believe there still exists a subgroup of patients with grade III AVMs near the eloquent peri-Rolandic cortex in which this approach may be safe and encouraging.

Citation: Muthana A, Alsubaihawi ZA, Dolachee AA, Almurayati ME, Atallah O, et al. (2023) Microsurgery for Grade III Cerebral Arteriovenous Malformations Related to the Eloquent Peri-Rolandic Territory: Case Series. Neurosurg Cases Rev 6:146. doi.org/10.23937/2643-4474/1710146

Accepted: October 09, 2023; **Published:** October 11, 2023

Copyright: © 2023 Muthana A, et al. This is an open-access article distributed under the terms of the Creative Commons Attribution License, which permits unrestricted use, distribution, and reproduction in any medium, provided the original author and source are credited.

Methods

Our study reviewed patients' data from September 2018 to March 2022 treated at the Baghdad Neurosurgery Teaching Hospital in Baghdad, Iraq. Patients with Spetzler-Martin grade III AVM located at peri-Rolandic areas that had been treated with microsurgery were included in this study. The peri-Rolandic territory involves the pre- and post-Rolandic areas, which represent the motor and sensory cortex, respectively.

An Analysis of 18 parameters was applied to each case; they are categorized into pre-, intra-, and post-operative factors. The pre-operative parameters include age, gender, presentation, Glasgow Coma Scale (GCS), neurological deficit, and AVM characteristics like location, size, eloquence, and venous drainage. Additionally, intra-operative parameters are also applied, including operation duration, blood loss, and brain swelling. Finally, Postoperative parameters are GCS, neurological deficits, AVM remnant, development of seizures, follow-up period, and modified Rankin Scale (mRS) at follow-up.

Results

From September 2018 to March 2022, a total of 8 Patients harboring a Spetzler-Martin grade III AVM with involvement of peri-Rolandic areas and treated by microsurgery are included in this study.

The patient population included 3 (37.5%) males and 5 (62.5%) females. The range of ages was between 13 and 53 (mean 30.8 years) and 3 patients were in the pediatric age group (≤ 18). The presenting symptom was a seizure in all the patients and no neurological deficit had been encountered preoperatively. All the AVMs had a negative rupture status at the time of presentation (Table 1).

The size of the AVM was between 35 mm and 54 mm and the venous drainage was superficial in all cases. Sensory-located AVM was found in 5 cases, and the remaining 3 cases have motor-located AVMs. All patients underwent elective surgery and the operation duration was between 7-9 hours. Regarding postoperative parameter, 6 patients developed new neurological deficits (4 weakness and 2 dysphasia), which were resolved in the subsequent follow-up. The follow-up period was 2-3 years and the mRS score at follow-up was 1 in all cases. Only one case has AVM remnant and 2 cases developed a seizure in the follow-up period (Table 2).

We present the first two cases as case scenarios to represent an example of our case series: one is motor AVM (Figure 1) and the other is sensory AVM (Figure 2).

Discussion

The Spetzler-Martin classification is the most widely

Table 1: Grade III peri-Rolandic AVM; Pre-operative parameters.

Cases	Gender	Age (years)	Presentation	Pre-op GCS	Pre-op deficit	AVM location	AVM size (mm)	Eloquence	Venous drainage
1	M	30	Seizure	15	No	L. frontal	40	Motor	Superficial
2	F	49	Seizure	15	No	R. parietal	35	Sensory	Superficial
3	M	48	Seizure	15	No	L. parietal	50	Sensory	Superficial
4	F	13	Seizure	15	No	L. frontal	42	Motor	Superficial
5	F	16	Seizure	15	No	L. frontal	46	Motor	Superficial
6	F	20	Seizure	15	No	L. parietal	48	Sensory	Superficial
7	F	18	Seizure	15	No	L. parietal	54	Sensory	Superficial
8	M	53	Seizure	15	No	L. parietal	50	Sensory	Superficial

M: Male; F: Female; GCS: Glasgow Coma Scale; AVM: Arteriovenous Malformation; L: Left; R: Right

Table 2: Grade III peri-Rolandic AVM; Intra and post-operative parameters.

Cases	Surgery duration (hours)	Blood loss (liter)	Brain swelling	Post-op GCS	Temporary post-op deficit	Follow-up seizure	AVM remnant	Follow-up period (years)	mRS
1	7	1	No	15	weakness	No	No	2	1
2	9	2	No	15	weakness	No	No	3	1
3	8	2	No	15	No	No	No	2	1
4	6	1	No	15	weakness	Yes	Yes	3	1
5	7	2	No	15	dysphasia	Yes	No	3	1
6	8	1	No	15	weakness	No	No	2	1
7	8	2	No	15	dysphasia	No	No	2	1
8	8	2	No	15	No	No	No	2	1

GCS: Glasgow Coma Scale, AVM: Arteriovenous Malformation; mRS: modified Rankin Scale

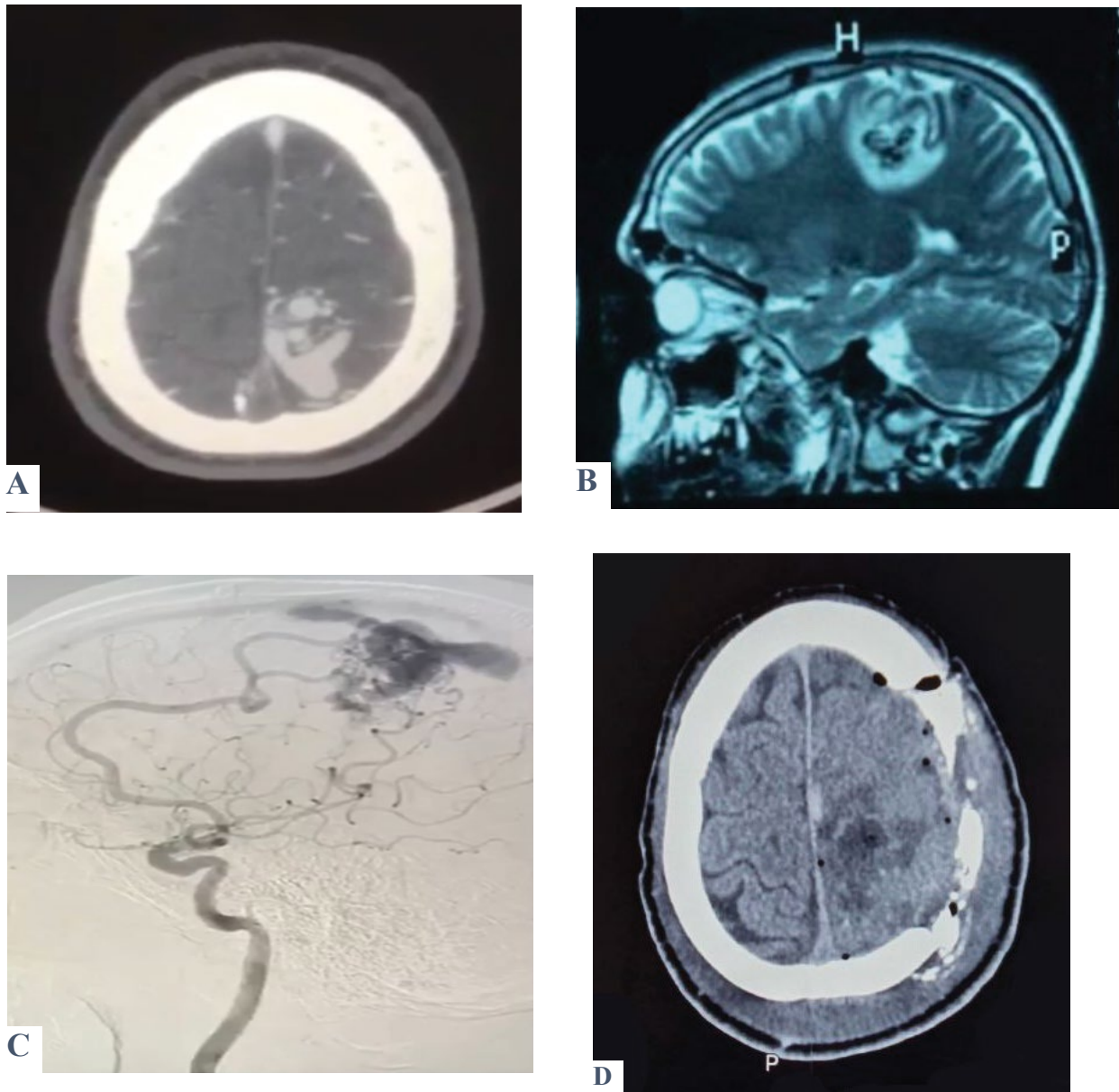


Figure 1: Shows a case of a 30-year-old male presented with two attacks of seizures associated with recurrent episodes of nausea and vomiting. On examination, there was no motor or sensory deficit, Glasgow coma score (GCS) was 15 with no fit or vomiting. A brain CT scan (A) was ordered and showed a left parietal AVM confirmed by MRA (B). DSA was performed to reveal exactly the location and characteristics of the feeding arteries and draining veins (C). Post-operatively, the patient's GCS was 15 with no fit and only one episode of vomiting. Motor examination revealed a decrease in the initiation of movement; otherwise, the patient was improved. Post-operative CT was done and showed total excision of the AVM (D).

accepted system for pre-operative AVM evaluation [1]. It has been extensively used because of its ease, simplicity, and practicality. Nevertheless, the classification can be misleading in some cases. One possible drawback of this system is that it lacks the ability to properly define the type of eloquent areas; consequently, patients with eloquent sensorimotor AVM are equal to patients with other eloquent AVM, for example, visual cortex AVM, and have the same grade [7].

Grade III AVM represents a dilemma and exemplifies the controversial paradigm of the Spetzler-Martin classification. It may include any combination of size, eloquence, and venous drainage. In the proposed 3-tier system by Spetzler-Ponce, Grade III AVMs remain

separate as Class B and receive multimodality treatment [2]. Consequently, the management plan for grade III AVM is yet an unresolved problem, and for that reason, many papers have been published in the literature discussing various modalities and subclassifications for this grade [3,4,8,9].

For the grade III peri-Rolandic AVM, as in our case series, all the AVMs should involve an eloquent area (one point) and have superficial venous drainage (zero point); this obligates the size to be between 3-6 cm to receive two points and become grade III. The clinical presentation of this lesion is typically seizure, as in all our cases. The peri-Rolandic territory involves the pre- and post-Rolandic areas, which represent

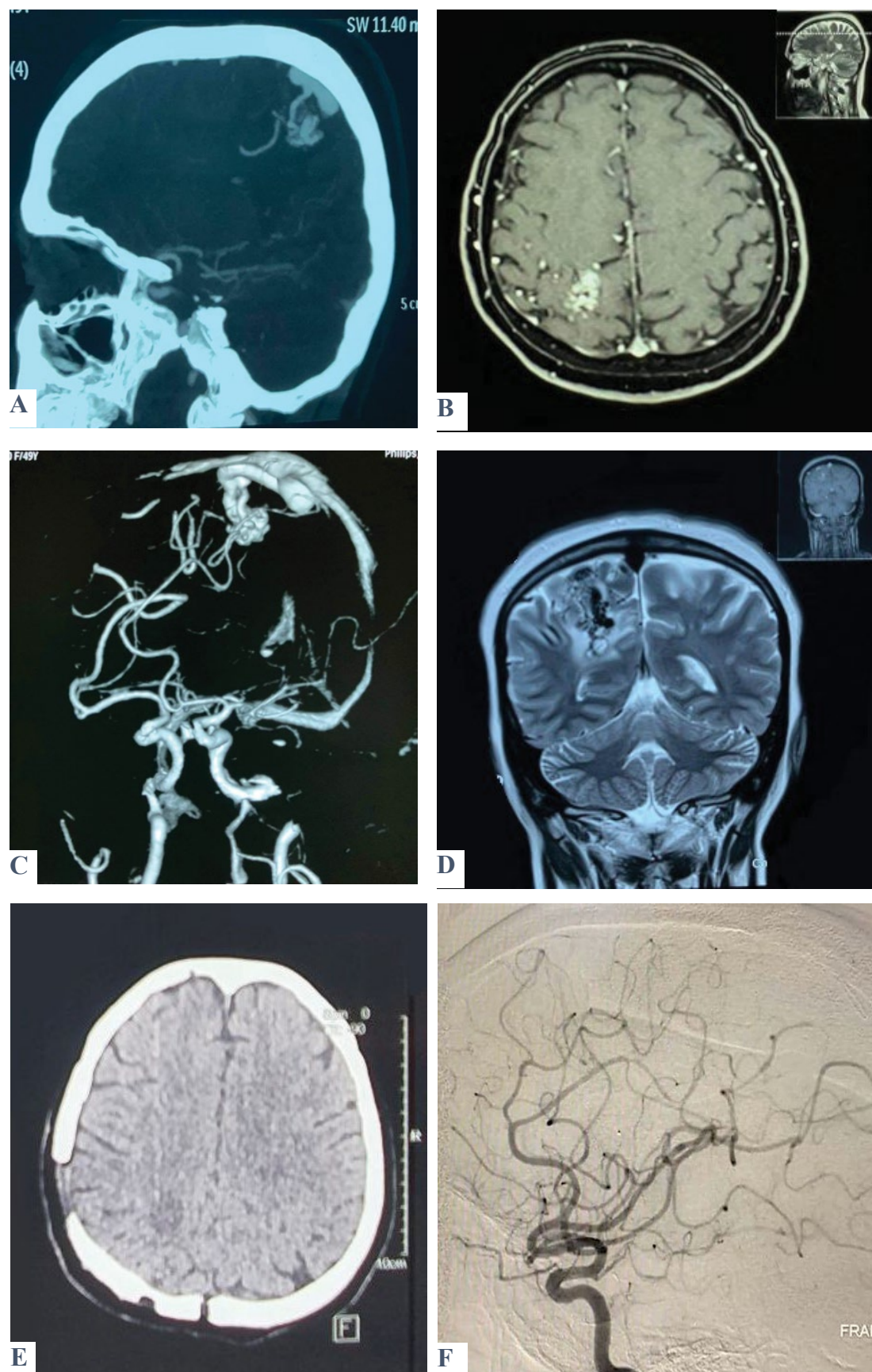


Figure 2: Shows a case of a 49-year-old female patient presented with three attacks of seizures. On admission, GCS was 15, with no fit, no vomiting, and no motor or sensory deficit. A brain CT scan (A) and MRI (B) show a heterogenous lesion within the posterior part of the Rt. parietal lobe involving the sensory area consistent with AVM, which was confirmed by MRA (C) and MRV (D). Post-operatively, GCS was 15 with no fit or vomiting. There was left-lower limb weakness but relieved on successive days. A postoperative brain CT scan and DSA revealed total excision of the lesion (E & F).

the motor and sensory cortex, respectively. In our case series, we found 3 motor and 5 sensory grade III AVMs, which represent sensory dominance, despite the small number of patients. We believe that peri-Rolandic areas are the most critical and eloquent areas that have diverse functional and clinical outcomes. A study found that sensorimotor eloquence would have a greater association with poor outcomes than the other eloquence subtypes [8], and although eloquent sensorimotor AVMs may receive the same Spetzler-Martin grade as an otherwise equivalent AVM of the visual cortex, the risk of a poor outcome may be higher with the former.

The management of grade III AVMs with an eloquent involvement is individualized and multimodal. The most common management options used are embolization and radiosurgery due to the perceived surgical risk [6]. Many authors support radiosurgical management since it is more appealing and essentially devoid of immediate treatment-related complications [4], while others go with endovascular management, which expands the ability to treat a wider range of AVMs [5]. However, in certain lesions, like peri-Rolandic AVMs, microsurgical resection is possible, especially for superficial, small-sized lesions. Indeed, microsurgery is still the most promising and ultimate method; it has been demonstrated to be superior in terms of overall risk reduction of future hemorrhage, primarily by means of obliteration rates nearing 100% [10-13]. In peri-Rolandic AVM, microsurgery is favorable and yields excellent AVM obliteration with minimal neurological morbidity in selected patients where the lesion is small in size and readily accessible through the cerebral fissures, which makes the resection smooth and straightforward [14].

The difficulty and risks involved with the surgical resection of grade III peri-Rolandic AVMs and the prognosis of these lesions are completely different. Unlike other types of eloquent AVMs, sensorimotor AVMs have worse outcomes and more neurological deficits after microsurgical resection [7]. However, most of these deficits are relieved in the long-term follow-up. In our case series, the majority of the patients (75%) developed postoperative deficits in the form of weakness and dysphasia, and a postoperative seizure was detected in two of the motor AVMs. Subsequently, on the long-term follow-up, these deficits were relieved, and the mRS score for all our patients was 1. This denotes that the frequency of disabling permanent neurological complications is nearly zero, which goes with the generally reported low complication rate of AVM microsurgery [15].

This study has a number of limitations, predominantly due to its retrospective nature. All the patients derived from a single center. The small number of included patients is the main limitation factor; It prevents accurate results and lacks the grand diversity of clinical presentation.

In our study, we believe there still exists a group of patients harboring grade III AVMs in the peri-Rolandic area for whom the microsurgical management is demanding and challenging, but promising and heartening.

Conclusion

Microsurgical management remains more effective in treating Spetzler-Martin grade III AVMs when the peri-Rolandic eloquent area is involved. This is due to the precise control and visualization provided by microsurgical techniques, which allow for safer resection of the AVM while minimizing damage to important brain functions.

Conflict of Interest and Financial Support

The authors have no Conflict of interest and financial support to disclose.

References

- Spetzler RF, Martin NA (1986) A proposed grading system for arteriovenous malformations. *J Neurosurg* 65: 476-483.
- Spetzler RF, Ponce FA (2011) A 3-tier classification of cerebral arteriovenous malformations. *Journal of neurosurgery* 114: 842-849.
- Pandey P, Marks MP, Harraher CD, Westbroek EM, Chang SD, et al. (2012) Multimodality management of Spetzler-Martin Grade III arteriovenous malformations. *J Neurosurg* 116: 1279-1288.
- Ding D, Yen CP, Starke RM, Xu Z, Sun X, et al. (2014) Radiosurgery for Spetzler-Martin grade III arteriovenous malformations. *J Neurosurg* 120: 959-969.
- Mounayer C, Hammami N, Piotin M, Spelle L, Benndorf G, et al. (2007) Nidal embolization of brain arteriovenous malformations using Onyx in 94 patients. *AJNR Am J Neuroradiol* 28: 518-523.
- Gamble AJ, Schaffer SG, Nardi DJ, Chalif DJ, Katz J, et al. (2015) Awake craniotomy in arteriovenous malformation surgery: The usefulness of cortical and subcortical mapping of language function in selected patients. *World Neurosurg* 84: 1394-1401.
- Mascitelli JR, Yoon S, Cole TS, Kim H, Lawton MT (2018) Does eloquence subtype influence outcome following arteriovenous malformation surgery? *J Neurosurg* 131: 876-883.
- de Oliveira E, Tedeschi H, Raso J (1998) Comprehensive management of arteriovenous malformations. *Neurol Res* 20: 673-683.
- Lawton MT (2003) UCSF brain arteriovenous malformation study project: Spetzler-Martin Grade III arteriovenous malformations: Surgical results and a modification of the grading scale. *Neurosurgery* 52: 740-749.
- Davidson AS, Morgan MK (2010) How safe is arteriovenous malformation surgery? A prospective, observational study of surgery as first-line treatment for brain arteriovenous malformations. *Neurosurgery* 66: 498-505.
- Nussbaum ES, Heros RC, Camarata PJ (1995) Surgical treatment of intracranial arterio-venous malformations with an analysis of cost-effectiveness. *Clin Neurosurg* 42: 348-369.

12. Pikus HJ, Beach ML, Harbaugh RE (1998) Microsurgical treatment of arteriovenous malformations: Analysis and comparison with stereotactic radiosurgery. *J Neurosurg* 88: 641-646.
13. van Beijnum J, van der Worp HB, Buis DR, Salman RA, Kappelle LJ, et al. (2011) Treatment of brain arteriovenous malformations: A systematic review and meta-analysis. *JAMA* 306: 2011-2019.
14. Cho N, Nga VD, Ahmed R, Ku JC, Munarriz PM, et al. (2020) Surgical management of pediatric rolandic arteriovenous malformations: A single-center case series. *J Neurosurg Pediatr* 27: 62-68.
15. Hartmann A, Stapf C, Hofmeister C, Mohr JP, Sciacca RR, et al. (2000) Determinants of neurological outcome after surgery for brain arteriovenous malformation. *Stroke* 31: 2361-2364.