



## ORIGINAL ARTICLE

## The Value Barium Swallow in the Diagnosis of Head and Neck Cancer Patients, a Validity of study

Mahmoud Elsayed, FRCS ORL-HNS<sup>1</sup> , Dena Elsayy, MBChB (Hons) BSc<sup>2</sup> , Abdelrahman Ezzat, FRCS ORL-HNS<sup>1\*</sup> and Phillip Moore, FRCS ORL-HNS<sup>1</sup> 

<sup>1</sup>Betsi Cadwaladr University Health Board, United Kingdom

<sup>2</sup>Leicester General Hospital, United Kingdom

\*Corresponding author: Abdelrahman Ezzat, FRCS ORL-HNS, Betsi Cadwaladr University Health Board, United Kingdom



### Abstract

Globus pharyngeus is a common benign condition. Patients with this condition are commonly investigated to exclude the risk of upper aero-digestive malignancies. One of the investigations carried out is barium swallow. However, there is great debate regarding the role of barium swallow in the diagnosis of head and neck cancers. Therefore, the aim of this study is to review the validity of barium swallow in diagnosing malignancies. All patients diagnosed with head and neck cancer between January 2010 and December 2014 in North Wales were included in the study (708 patients). Results showed that 35 patients had barium swallow before the diagnosis of cancer. Barium swallow suspected malignancy in only 5 patients and missed the cancer diagnosis in 30 patients. Therefore, the study confirms that that barium swallow has a very limited sensitivity and specificity in diagnosing head and neck cancer. In conclusion, barium swallow should not be requested routinely as part of the investigation of cases suspected to have head and neck cancer. This approach will reduce the cost and radiation effect of unnecessary investigations.

### Introduction

Globus pharyngeus is a common condition which represents 3-4% of new referrals to the ENT outpatient clinic [1-3]. It is defined as a feeling of a 'lump' in the throat. The exact aetiology and management of the condition remains unclear [4]. Furthermore, there is a lack of consensus about the role of any investigation in its management [2]. The main aim of investigating patients with globus is usually to eliminate upper aero-digestive malignancies.

Barium swallow is the most commonly used non-invasive method of investigation. However, most of these

contrast investigations usually fail to demonstrate any serious pathology. Therefore, the aim of this study is to review the barium swallow reports carried out for patients diagnosed with head and neck cancer before the date of diagnosis.

### Methodology and Results

The study includes all patients diagnosed with head and neck cancer in Betsi Cadwaladr University Health Board between January 2010 and December 2014. This data has been retrieved from the Head and Neck service in Ysbyty Gwynedd in Wales, UK.

Table 1 illustrates all 708 head and neck cancer patients included in the study. From these patients, 262 (37%) were females and 546 (77%) were males. Thyroid cancer is more common in females (68%).

Table 2, highlights the number of head and neck cancer patients diagnosed in each hospital within the trust respectively. The three main hospitals in the trust are Ysbyty Glan Clawd, Wrexham Hospital and Ysbyty Gwynedd.

In order to ensure that the barium swallow was carried out before the date of diagnosis, all 708 head and neck cancer cases were revised through the PACS synapse radiology system. Therefore, any case which had barium swallow after diagnosis of head and neck cancer or as part of the follow up of surgery or complication of treatment had been excluded from the study.

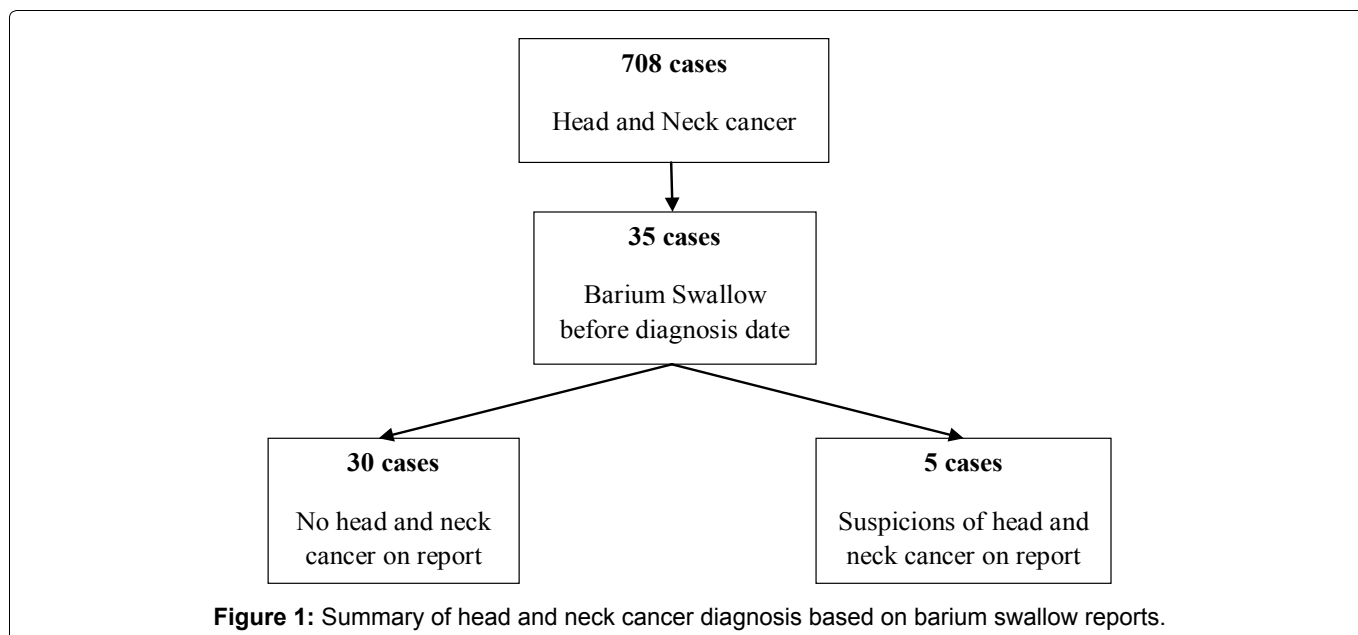
From these 708 patients, a total of 35 had a bari-



**Citation:** Elsayed M, Elsayy D, Ezzat A, Moore P (2020) The Value Barium Swallow in the Diagnosis of Head and Neck Cancer Patients, a Validity of study. J Otolaryngol Rhinol 6:081. doi.org/10.23937/2572-4193.1510081

**Accepted:** May 06, 2020; **Published:** May 08, 2020

**Copyright:** © 2020 Elsayed M, et al. This is an open-access article distributed under the terms of the Creative Commons Attribution License, which permits unrestricted use, distribution, and reproduction in any medium, provided the original author and source are credited.

**Table 1:** Head and neck cancer categories (2010-2014).

Cancer subtype	Total number	Males	Females
Larynx & Hypopharynx	192	148 (77%)	44 (33%)
Mouth & Oral Cavity	191	109 (57%)	82 (43%)
Tonsil & Oropharynx	176	130 (73%)	46 (27%)
Thyroid	93	30 (32%)	63 (68%)
Salivary	29	13 (44%)	16 (56%)
Nose & Nasopharynx	26	14 (54%)	12 (46%)
Other			1 (100%)

**Table 2:** Head and neck cancer patients diagnosed in each hospital (2010-2014).

Hospital	No. of patients diagnosed with head and neck cancer
Ysbyty Glan Clawd	244
Wrexham Hospital	240
Ysbyty Gwynedd	224

um swallow prior to the date of diagnosis of head and neck cancer. Out of the 35 patients, 30 were deemed to not have any head and neck cancer and it was only later picked up by other sensitive investigations; Computed Tomography (CT) and Magnetic Resonance Imaging (MRI). As a result of this false reassuring reports, the diagnosis of cancer had been delayed. In the remaining 5 cases, the barium swallow report recommended further investigations and rose suspicion of cancer. Three of these 5 patients had previous throat cancer. One patient had fungating filling defect in the hypopharynx and upper oesophagus. The last one had thyroid mass pressing on the pharynx.

Our data shows that the sensitivity of barium swallow in diagnosis of head and neck cancer is 15%. Barium swallow has very high false negative results (Figure 1).

## Discussion

Globus pharyngeus is a common problem of uncertain aetiology and of controversial management. Patients with this condition are commonly investigated to exclude the risk of upper aero-digestive malignancies. Around 45% of the general population experience globus sensation at some point in their lifetime [5,6]. Several factors are thought to be responsible including; cricopharyngeal spasm, lingual tonsil, granular pharyngitis, cervical osteophytosis, Gastroesophageal Reflux Disease (GORD), hiatus hernia, sinusitis, postnasal drip, goitre and finally psychiatric causes [6]. The clinical examination is almost always unremarkable. The relationship between GORD and globus is very controversial. While some studies identify a strong association, others deny such a relation. The reported association varied from 11% [7] to 55% [8]. The association of both hiatus hernia and reflux with globus is estimated to be 2-3% [9]. In another study of 116 barium swallow, cervical osteophytosis was found in about one third of the patients [10].

Barium swallows are usually requested to exclude pharyngeal and upper oesophageal neoplasia in patients with globus [7]. This is mainly to reassure patients and to eliminate serious pathology [10]. The sensitivity of barium swallow to diagnose small upper digestive tu-

mours is low and it is reported that it may fail to detect 50% of the hypopharyngeal carcinoma [4]. In a study of 2,011 barium swallow of patients with globus, no serious pathology was detected. Furthermore, no patients were diagnosed with cancer following 2 to 7 years of follow-up [9]. Extensive review of literature failed to identify any patient with globus diagnosed with upper aero-digestive malignancies [2,3,7]. Therefore, the indication of barium swallow in typical globus pharyngeus patients is very doubtful due to the investigations low sensitivity to detect small tumours. The investigation has both a radiation risk and cost implications. The radiation amount of one barium swallow study is equivalent to 75 chestX-rays [2]. The cost of each barium swallow is about £200. Therefore, this investigation is not considered cost-effective.

The management of globus is unclear as it is considered to be predominantly a clinical diagnosis requiring no investigation the majority of the time [2]. Current guidance suggests that in the presence of globus without any risk factors and normal clinical examination, there is no indication for further investigation unless the symptoms persist [7]. Despite this, a questionnaire study about the management of patients with typical symptoms of globus pharyngeus showed that 14% of the UK consultants perform no investigation. The remaining consultants suggest carrying out the following investigations; rigid endoscopy (61%), barium swallow (56%) or a combination (14%) [4]. A study suggested that Globus should be managed with a 1-month course of antacid to patients with typical globus followed by investigation if the symptoms persist [5].

Small post-cricoid carcinoma can be missed by barium swallow and only rigid endoscopy can confirm the final diagnosis [4]. Comparing rigid endoscopy, flexible endoscopy and barium swallow, the first is considered the most sensitive diagnostic test for the upper aero-digestive tract malignancies [11-13]. Flexible oesophagoscopy may miss hypopharyngeal tumours and the rigid endoscopy is essential in these cases [14].

Patients with upper aero-digestive tumours typically divided into two groups based on tumour size. The first group includes patients with large tumours and the diagnosis is usually obvious on clinical examination and fiberoptic examination. In our study, the only 2 primary cancer cases diagnosed with barium swallow could have been diagnosed by complete clinical examination with fiberoptic examination without the need for barium swallow. The second group includes patients with small tumours and negative clinical signs. Barium swallow usually will fail to diagnose these small lesions. For this group, more sensitive investigations; MRI scan and CT scan should be requested.

The study confirms reduced validity of barium swallow in globus pharyngeus and head and neck cancer patients. For example, a patient diagnosed with a T4a cancer tongue base was missed by barium swallow. In

another case, barium swallow suspected a lesion on the right side whereas the MRI scan confirmed a large mass on the left side.

Our study is clearly showing that barium swallow is not helpful investigation for patients presented with symptoms suspicious for cancer.

## Conclusion

The role of barium swallow in the management of globus pharyngeus is controversial. Barium swallow is usually prescribed to exclude the presence of upper aero-digestive malignancies. It has low sensitivity to diagnose small pharyngeal and oesophageal tumours while larger tumours are usually obvious on clinical examination.

## References

1. Batch AJ (1988) Globus pharyngeus (Part 1). *J Laryngol Otol* 102: 152-158.
2. Harar RPS, Kumar S, Saeed MA, Gatland DJ (2004) Management of globus pharyngeus: review of 699 cases. *J Laryngol Otol* 118: 522-527.
3. Rowley H, O'Dwyer TP, Jones AS, Timon CI (1995) The natural history of globus pharyngeus. *Laryngoscope* 105: 1118-1121.
4. Webb CJ, Makura ZGG, Fenton JE, Jackson SR, McCormick MS, et al. (2000) Globus pharyngeus: a postal questionnaire survey of UK ENT consultants. *Clin Otolaryngol* 25: 566-569.
5. Bradley PJ, Narula A (1987) Clinical aspects of pseudodysphagia. *J Laryngol Otol* 101: 689-694.
6. Kerr AG (1997) Scott-Brown's otolaryngology. In: Wilson JA, Laryngology and head & neck surgery. volume 5, Reed Educational and Professional Publishing Ltd., Oxford. The oesophagus in otolaryngology, Chap 24, 1-31.
7. Back GW, Leong P, Kumar R, Corbridge R (2000) Value of barium swallow in investigation of globus pharyngeus. *J Laryngol Otol* 114: 951-954.
8. Timon C, O'Dwyer T, Cagney D, Walsh M (1991) Globus pharyngeus: long-term follow-up and prognostic factors. *Ann Otol Rhinol Laryngol* 100: 351-354.
9. HajioV D, Lowe D (2004) The diagnostic value of barium swallow in globus syndrome. *Int J Clin Pract* 58: 86-89.
10. Caylakli F, Yavuz H, Erkan AN, Ozer C, Ozluoglu LN (2006) Evaluation of patients with globus pharyngeus with barium swallow pharyngoesophagography. *Laryngoscope* 116: 37-39.
11. Bacon CK, Hendrix RA (1992) Open tube versus flexible esophagoscopy in adult head and neck endoscopy. *Ann Otol Rhinol Laryngol* 101: 147-155.
12. Curran AJ, Barry MK, Callanan V, Gormley PK (1995) A prospective study of acid reflux and globus pharyngeus using a modified symptom index. *Clin Otolaryngol Allied Sci* 20: 552-554.
13. Levine B, Nielson EW (1992) The justifications and controversies of the panendoscopy--a review. *Ear Nose Throat J* 71: 335-340.
14. Bingham BJ, Drake-Lee A, Chevretton E, White A (1989) Pitfalls in the assessment of dysphagia by fiberoptic oesophagogastrosocopy. *Ann R College Surg Engl* 68: 22-23.