



## CLINICAL IMAGE

### Interesting Pustules on Pinna

Saliha KARATAY<sup>1\*</sup> and Berrire KURT<sup>2</sup>

<sup>1</sup>Department of Physical Medicine and Rehabilitation, Ankara, Turkey

<sup>2</sup>Department of Family Medicine, Cemal Pamuk Family Health Center, Istanbul, Turkey

\*Corresponding author: Saliha Karatay, MD, Professor, Department of Physical Medicine and Rehabilitation, 06500 Ankara, Turkey, Tel: +90-312-2162611, E-mail: [skaratay73@gmail.com](mailto:skaratay73@gmail.com)



#### Keywords

Acupuncture, Pustule, Pinna, Osteoarthritis

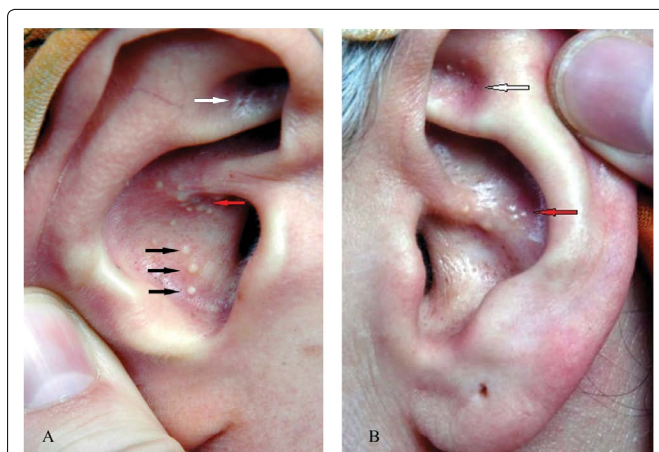
A 56-year-old female patient with osteoarthritis of the knee is presented pustules in her ear corresponding to knee and gastrointestinal auricular points. When she came to our clinic, her primary complaint was knee and hip pain. She had a history of generalized osteoarthritis for eight years. She had tried paracetamol, NSAIDs and hyaluronic acid injections as well physical therapy. Her pain was assessed at 8 by visual analog scale (VAS). We

decided to treat her with acupuncture. In inspection of her ear for auriculotherapy, we described interesting located pustules on points corresponding to knee (Figure 1A and Figure 1B, white arrows) lung (Figure 1A black arrows) and gastrointestinal system, esophagus, stomach and small intestine (Figure 1A and Figure 1B, red arrows) in both pinna.

The patient did not report any problems with digestive and respiratory systems in her primary intake. Upon further inquiry, she reported that she was diagnosed with peptic ulcer in stomach and duodenum and complained of nausea. With her acupuncture treatment, we addressed gastrointestinal problems, as well as her knee. Treatment protocol included; SP 9, ST 40, ST 36, ST 35, EX-LE5 (Xiyian), SP 6 and Ren 12 acupuncture points. She was treated once week for 2 months, her pain levels in the knee went down to 4 in VAS scale. She was referred to gastroenterology and pulmonary department for further assessment.

#### Financial Support or Conflict Interests

No.



**Figure 1:** Pustules on pinnas bilaterally. A) Shows pustules on points of knee (white arrow), lung (black arrows) and gastrointestinal system such as esophagus, stomach and small intestine (red arrow) on right pinna according to Nogier auriculotherapy; B) Shows pustules on points of knee (white arrow) and gastrointestinal system such as esophagus, stomach and small intestine (red arrow) on left pinna according to Nogier auriculotherapy.