



Laryngeal Tuberculosis: About 3 Cases from Morocco

Abou-elfadl M*, Benzaouia A, Abada R, Rouadi S, Roubal M and Mahtar M

Department of Otorhinolaryngology and Neck Surgery, 20August Hospital, Casablanca, Morocco

*Corresponding author: Dr. Abou-elfadl Maryame, Resident of the Otorhinolaryngology and Neck Surgery department, 20August Hospital, PO Box 9619 Moulay Rchid, Casablanca, Morocco, Tel: +212-6679-32692, E-mail: maryameabouelfadl@gmail.com

Summary

Introduction: Tuberculosis is a public health problem in developing countries; pulmonary localization is the most common and contagious. Laryngeal localization is rare; it can be primary or secondary often.

Materials and methods: Presents three cases of laryngeal tuberculosis revealed by atypical clinical and endoscopic tables, of which only the histology was confirmed diagnosis.

Discussion: Laryngeal tuberculosis (TL) is often taken for laryngeal cancer or a specific or nonspecific laryngitis, which delayed diagnosis, a source of danger for the health public because of the contagiousness. Only histology confirms the diagnosis and allows initiating adapted antituberculosis drugs treatment that ensures healing.

Keywords

Dysphonia, Tuberculosis, Larynx, Biopsy, Antituberculosis drugs

Introduction

The laryngeal tuberculosis incidence decreased significantly since the development of antituberculosis drugs and early detection of new cases. Currently, it represents less than 1% of cases of extrathoracic tuberculosis. As tuberculosis is endemic in Morocco, we continue to see this rare localization. Its clinical presentation is atypical and endoscopic aspects are polymorphic, hence the difficulty of diagnostic. The aim of the study is to report three different observations of the laryngeal localization of tuberculosis.

Materials and Methods

We collected during the year 2014, 3 cases of laryngeal tuberculosis diagnosed in service and treated in the specialized center for tuberculosis.

Results

Observation n°1: laryngeal tuberculosis revealing a miliary tuberculosis

A thirty year old male, 10 pack year smoking, presented a chronic dysphonia, isolated, without cough or dyspnea, or dysphagia with weight loss notion.

Clinical examination revealed, in nasofibroscope, tumor in the larynx. There was no neck stiffness or enlarged lymph nodes or signs of meningeal irritation or localising neurological deficit. Chest

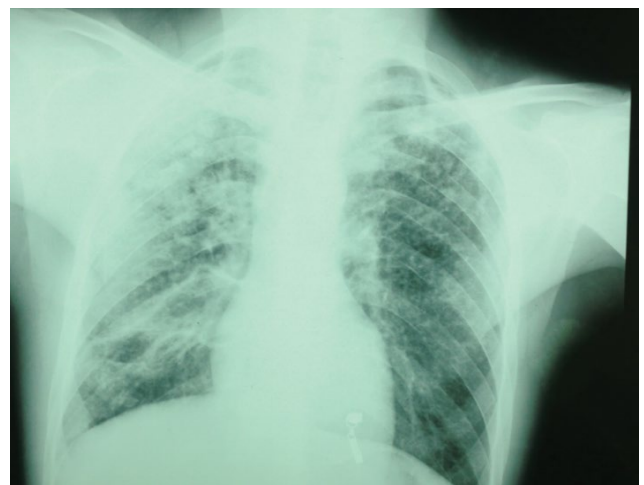

Figure 1: Chest radiography revealed wide spread nodular opacities distributed throughout both lungs.

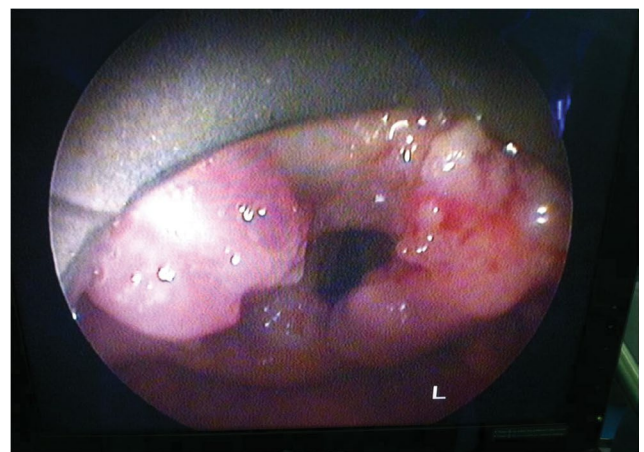


Figure 2: Tumor of arytenoids in nasofibroscope.

radiography revealed wide spread small (2-4 mm) nodular opacities distributed throughout both lungs (Figure 1). Direct laryngoscopy revealed a tumor taking all the epiglottis, the two ventricular bands and the two arytenoid (Figure 2), the piriform sinus, the sub-glottis

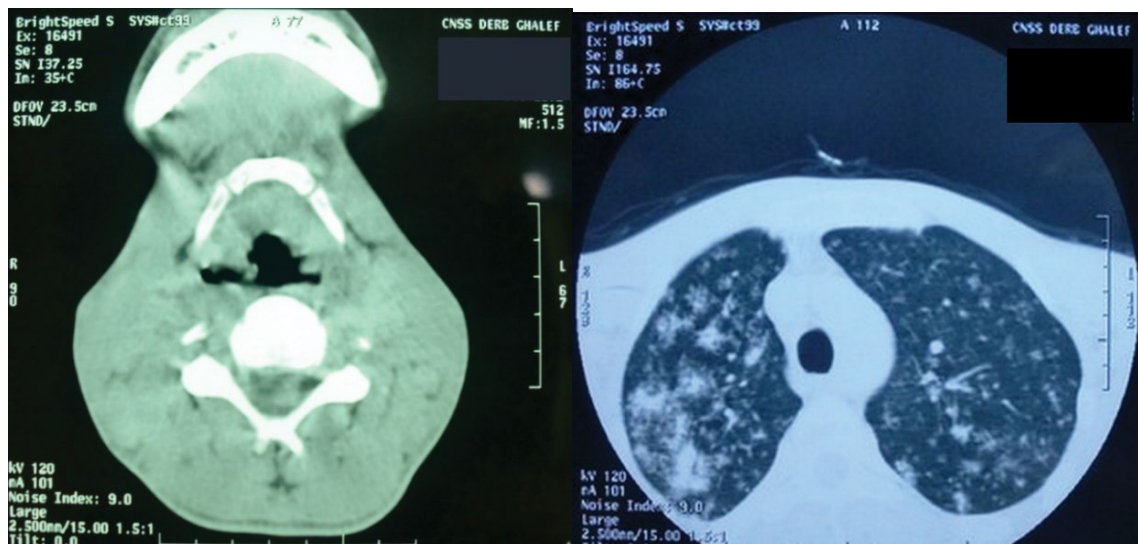


Figure 3: Cervicothoracic scanner that shows a glotto-sus-glottic tumor associated with macronodules of both lung fields.

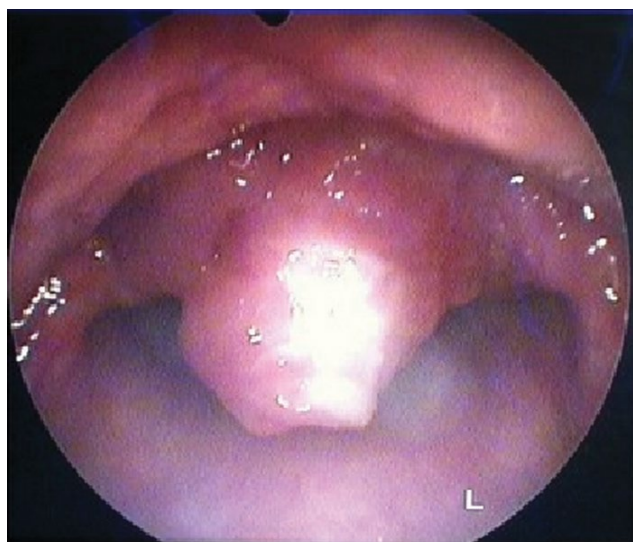

Figure 4: Nasofibroscope showing tumor of epiglottis.

Observation 3: Concomitant laryngeal and pulmonary tuberculosis.

Forty one years old male, 30 pack years smoking, consulted for dysphagia, dysphonia, and a productive cough evolving for three months in a context of fever, night sweats and weight loss without dyspnea. Clinical examination found a febrile patient with bilateral lung sounding rales and swelling at the level of the epiglottis in Nasofibroscope (Figure 4). There was no neck enlarged lymph nodes. Chest radiography showed a bilateral interstitial infiltrate, TST and 3BKsputum were positives.

Direct laryngoscopy objectified a lesion in the epiglottis which biopsies were incomes for a gaseous necrosis tuberculosis of larynx. A quadruple tuberculosis is introduced in specialized center. The outcome was favorable with regression of symptoms, negativity of Koch's Bacillus sputum and disappearance of laryngeal lesions.

Discussion

Laryngeal tuberculosis (LT) is a specific chronic laryngitis caused by *mycobacterium tuberculosis*. Centers for Disease Control and Prevention ranked laryngeal TB as "a highly contagious form of tuberculosis, including erosive and exudative invasion of the larynx" [1].

LT represents 1% of all TB localizations [2] and the most common location in the ENT [3]. It can be seen at any age, but especially in young adults between 20 and 50 years [2].

Tuberculosis is an airborne disease, transmitted from person to person. Koch's bacillus can reach the larynx by two different ways: directly from the external environment, realizing the primary laryngeal tuberculosis or indirectly from another focus and realizing the secondary laryngeal tuberculosis [1,3].

Clinically, it is difficult to differentiate tuberculosis and malignant tumors of the larynx [2,3]. The symptoms are atypical: hoarseness, weight loss, fatigue, persistent dry cough, fever, sweats, and sleep apnea, in an often chronic alcohol and tobacco subject [2].

In the literature, no asphyxiant form has been described justifying resuscitation measures such as intubation or a tracheostomy [4]. Physical examination may find cervical lymph nodes in 10% of cases [5]. Laryngoscopy are also contributive, with an aspect that may primarily evoke cancer or chronic laryngitis, but also other granulomatous diseases such as syphilis, sarcoidosis, Wegener's granulomatosis [2,3,5-7].

Gallasand, et al. study show that the laryngeal tuberculosis is essentially glottic with a predominant involvement of the vocal cords

and esophageal mouth are free, basic language is flexible. The biopsy with histological examination revealed chronic inflammation with epithelioid granuloma giant cell without necrosis.

The assessment completed by a cervicothoracic scanner that shows a glotto-sus-glottic tumor associated with macronodules of both lung fields (Figure 3). The tuberculin skin test (TST) and search of *Mycobacterium tuberculosis* (BK) in sputum were positive. The patient has antitubercular treatment in specialized center for tuberculosis with monitoring and testing the entourage.

Observation n°2: isolated laryngeal tuberculosis

Forty six years old male, 12 pack year smoking and chronic alcoholic, consults for isolated and permanent dysphonia, evolving since 9 months, in a context of impaired general condition. We found in nasofibroscope an irregular and inflammatory laryngeal mucosa. There was no cervical lymphadenopathy or other defects.

Direct laryngoscopy showed an irregular and inflamed aspect of laryngeal mucosa, ventricular band, epiglottis and arytenoid. The biopsy with histological examination revealed chronic inflammation with epithelioid granuloma giant cell without caseous necrosis. The TST was positive (20 mm), the chest radio was normal and 3 sputum BK were negatives. The patient has antitubercular treatment. The lesions was completely regressed.

Table 1: Different cases of laryngeal tuberculosis from the literature.

Authors and year of publication	Clinical presentation	Laryngoscopy	Biopsy and histology	Bronchoscopy or others	Treatment and evolution
Kumar 2014 [6]	-55-year-old male -Chronic tobacco chewer -Progressive foreign body sensation in throat and change in voice for last three months	-Diffuse edema of epiglottis, bilateral aryepiglottic folds and false cords	-Stratified squamous epithelium with epitheloid granuloma and Langhans giant cell surrounded by lymphocytes suggestive of tuberculosis	-Purulent discharge coming from the left upper lobe bronchus and bronchoalveolar lavage were taken which showed mycobacterium tuberculosis on culture by bactec method	2RHZE/4RH -Complete resolution of symptoms and swelling after 2 month
Bhuyan 2014 [3]	-49-year-old -Non-smoker	-Insidious onset hoarseness, dry cough and anorexia of 2 months duration	-Congested laryngeal and pharyngeal mucosa	-Stratified squamous epithelium with subepithelial infiltration with inflammatory cells comprising mainly with lymphocytes and Langerhan's type giant cells suggestive of a granulomatous inflammation due to TB without any evidence of malignancy	2RHZE/4RH -Complete resolution of symptoms after 1 month
Chen 2012 [7]	47-year-old	-Throat discomfort especially when swallowing and an unproductive cough	-Thickened, irregular and friable lesion on the epiglottis	-Necrotic granulomatous inflammation, a single acid fast bacillus on Ziehl-Neelsen stain and no evidence of malignancy -Pulmonary shadowing in the right upper zone in chest radiograph	2RHZE/4RH -Complete resolution of symptoms after 1 month

(64.8% of cases) followed by vestibular folds (34.9% cases) [5]. According to Lim et al, the proportions were 46 and 18% respectively [5].

More rarely, tuberculous granulomas concern the arytenoid, the posterior commissure and epiglottis [5].

Once the diagnosis is confirmed by histological and bacteriological studies, the search for other focus point of tuberculosis, especially lung disease. The adequate management and starting antituberculosis drugs ensure healing without sequelae [4,5] (Table 1).

Conclusion

Laryngeal tuberculosis is rare. Often it is not isolated and can sometimes reveal clinically unrecognized pulmonary tuberculosis. A few specific symptoms and endoscopic semiology can refer to wrongly malignancy until bacteriological results. The latest techniques of cultivation and genomic diagnostics allow rapid diagnosis of tuberculosis. The standard tuberculosis treatment allows complete mucosal healing of the larynx and quickly stops any risk of human transmission.

References

- Hans L Rieder (2009) La contagiosité de la tuberculose laryngée: action de santé publique appropriée basée sur des prémisses inexactes. *Int J Tuberc Lung Dis* 13: 4-5.
- Mandal A, Ray S, Ganguly (2014) Study to evaluate clinicopathological profile of laryngeal tuberculosis. *BBB* 2: 742-747.
- Bhuyan N, Das AK (2014) Primary laryngeal tuberculosis: a rare cause of chronic laryngitis. *Int J Adv Med* 1: 279-281.
- Margery J, Grassin F, Lecoules S, Dot JM, Guigay J, et al. (2004) Atteinte laryngée révélatrice d'une tuberculose pulmonaire méconnue. *Rev Pneumol Clin* 60: 39-42.
- Saroul N, Vellin JF, Baud O, Nohra O, Kemeny JL, et al. (2008) Tuberculose épilaryngée: considérations épidémiologiques, cliniques et sanitaires, *Annales d'otolaryngologie et chirurgie cervico-faciale*. 125: 155-159.
- Kumar A, Singh DK, Arpit S, Singha S (2014) Tubercular Laryngitis Simulating Laryngeal Carcinoma. *J Pulm Respir Med* 5.
- Chen HK, Thornley P (2012) Laryngeal tuberculosis: A case of a non-healing laryngeal lesion. *Australas Med J* 5 : 175-177.