



LETTER TO THE EDITOR

Cerebral Aspergillosis in a Patient with p-ANCA Vasculitis: Serial Imaging Observation over 15 Months

Mei Chen Chen¹, Che Kim Tan² and Wen Liang Yu^{2,3*}

¹Department of Nursing, Chi Mei Medical Center, Tainan, Taiwan

²Department of Intensive Care Medicine, Chi Mei Medical Center, Tainan, Taiwan

³Department of Medicine, School of Medicine, College of Medicine, Taipei Medical University, Taipei, Taiwan

*Corresponding author: Wen Liang Yu, Department of Intensive Care Medicine, Chi Mei Medical Center, 901 Chung Hwa Road, 710 Tainan City, Taiwan, Tel: +886-628-12811, Fax: +886-628-33351, E-mail: Yuleon_md@yahoo.com.tw



To the Editor

Aspergillosis is well known in a patient with perinuclear Antineutrophilic Cytoplasmic Antibody (p-ANCA)-associated vasculitis and pulmonary renal syndromes [1]. However, only a few cases have been reported in ANCA-associated patients. Akimoto, et al. reported a patient of ANCA-associated vasculitis with corticosteroid therapy who had massive recurrent hemoptysis due to pulmonary *Aspergillus mycetoma* [1]. A disseminated aspergillosis with invasion of the lungs, heart, and brain developed following resolution of pneumocystis pneumonia in a patient receiving long-term prednisolone therapy for Good-pasture syndrome with positive ANCA, an autoimmune disease that attacks the lungs and kidneys [2]. In China, Su, et al. found 7 of 157 patients with ANCA-associated vasculitis developed Invasive Pulmonary Aspergillosis (IPA) [3].

A 64-year-old woman with chronic kidney disease had hemoptysis for 2 days. Soon, dyspnea and O₂ desaturation occurred. She was admitted to the Intensive Care Unit (ICU) on November 16, 2015. The blood urea nitrogen and creatinine were 96 and 8.9 mg/dL respectively. The immunological tests included antinuclear antibodies, 40 x; p-ANCA, 27.4 IU/mL (positive, > 5 IU/mL); Cytoplasmic ANCA, < 0.2 IU/mL and basement membrane zone antibody, < 20 x. As p-ANCA positive vasculitis with pulmonary renal syndrome was suspected, she received hemodialysis and intravenous methylprednisolone (40 mg every 6 hours). Her condition improved, so

she was transferred to the ward on 30 November.

Because the renal biopsy revealed p-ANCA-associated diffuse crescentic glomerulonephritis, an intravenous low-dose cyclophosphamide (200 mg) and double filtration plasmapheresis were initiated. The patient received methylprednisolone 160 mg daily for about 3 weeks from November 16 to December 5, which was then reduced to 40 mg every 12 hours from December 6, 2015. On December 7, a nodular lesion appeared in the right upper lung field (Figure 1A), of which the chest Computed Tomography (CT) revealed abscess appearance (Figure 1B). Meanwhile, *Aspergillus galactomanan* antigen tests (index) were 2.6 in blood sample and > 7.18 in the bronchoalveolar lavage fluid respectively (normal, < 0.5 index), so voriconazole was added on December 16. However, as her consciousness became disturbed, brain Magnetic Resonance Imaging (MRI) revealed hemorrhagic necrotic lesions at left frontotemporal and right temporoparietal regions (Figure 1C and Figure 1D). The family did not accept biopsy for the brain lesions. The methylprednisolone was discontinued on December 26, 2015.

The follow-up chest CT showed persistent lung abscess on January 30, 2016 (Figure 1E). CT-guided lung biopsy revealed the presence of fungal hyphae, supporting the diagnosis of IPA. However, the patient experienced a short course of pulmonary hemorrhage (Figure 1F). Follow-up brain CT revealed marked resolution of the brain lesions (Figure 1G). She was then discharged



Citation: Chen MC, Tan CK, Yu WL (2017) Cerebral Aspergillosis in a Patient with p-ANCA Vasculitis: Serial Imaging Observation over 15 Months. J Infect Dis Epidemiol 3:042. doi.org/10.23937/2474-3658/1510042

Received: July 30, 2017; **Accepted:** November 04, 2017; **Published:** November 06, 2017

Copyright: © 2017 Chen MC, et al. This is an open-access article distributed under the terms of the Creative Commons Attribution License, which permits unrestricted use, distribution, and reproduction in any medium, provided the original author and source are credited.

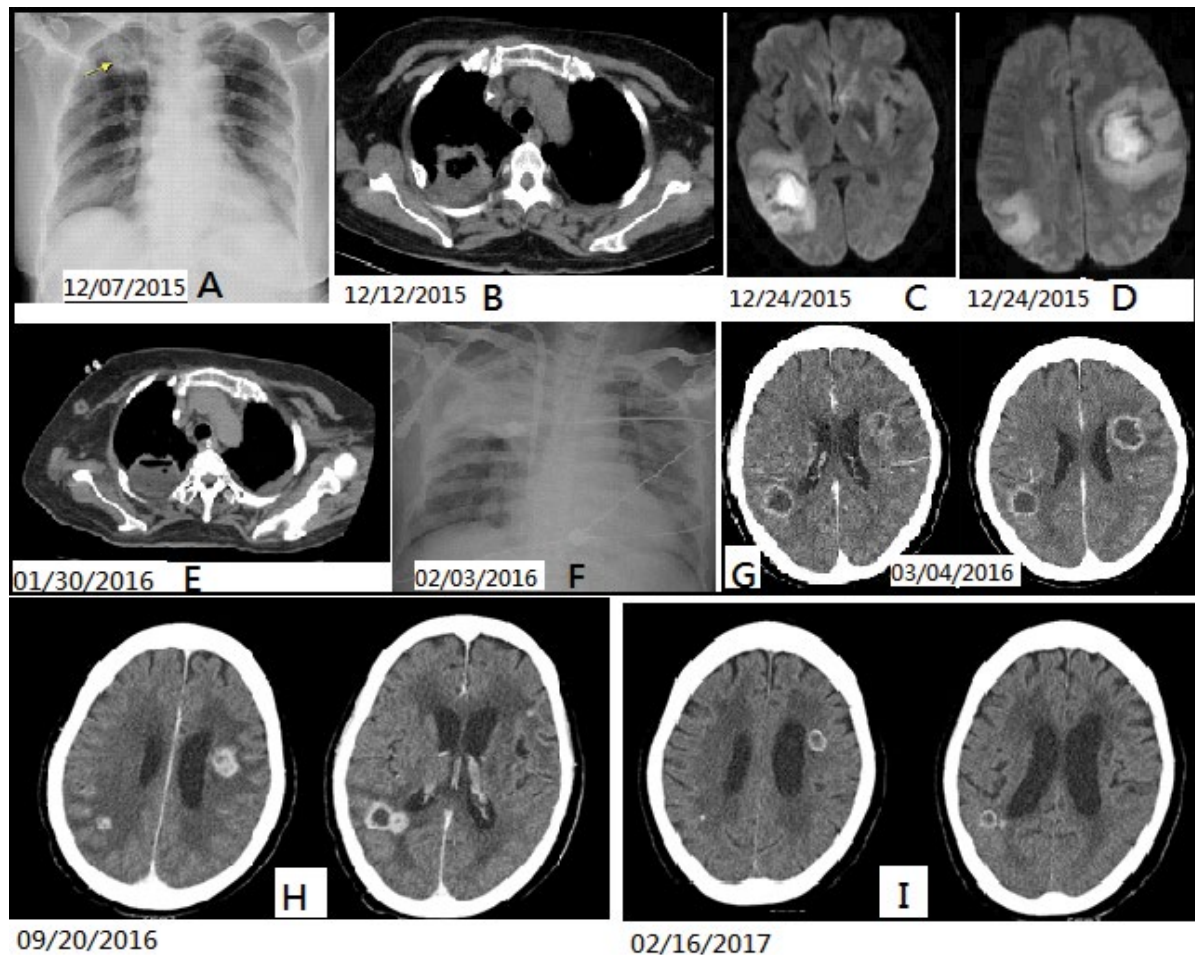


Figure 1: Chest X-ray film shows a nodular lesion in Right Upper Lung (RUL) field (A, arrow), which was suggestive of abscess formation by chest CT imaging; B) Brain MRI shows multiple hemorrhagic necrotic mass lesions, involving right temporoparietal and left frontotemporal regions; C,D) Follow-up chest CT scan shows persistent RUL lung abscess; E) Post-biopsy CXR shows consolidation over RUL; F) Indicating pulmonary hemorrhage clinically. Follow-up brain CT scans in post-voriconazole treatment; G,H) Subsequent posaconazole therapy (I) Show significant resolution of brain lesions, favoring cerebral aspergillosis.

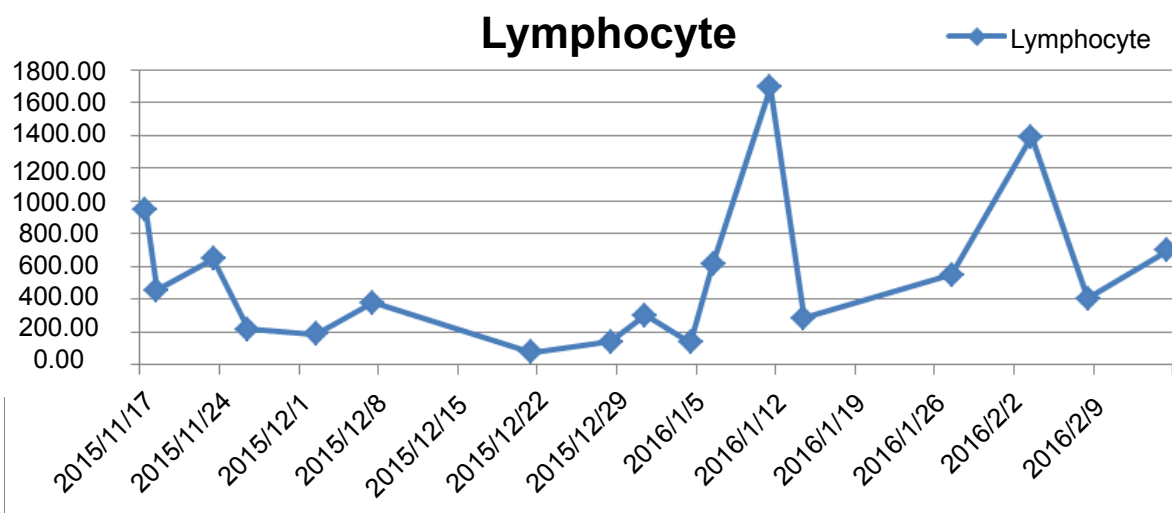


Figure 2: Throughout the course of first hospitalization, the patient had prolonged lymphocytopenia with a lymphocyte of less than 1,000/ μ L for most of the time when the blood was tested.

with stable condition on March 5, 2016. Throughout the course, the patient had lymphocytopenia with a lymphocyte of less than 1000/ μ L for most of the time when the blood was tested (Figure 2).

The patient was readmitted to the hospital due to a seizure attack on August 22, 2016. During this episode, she underwent navigator-assisted brain biopsies for left frontal and right parietal brain lesions, which

Table 1: Clinical course and antifungal progression of our case.

	Admission to the hospital 16 November, 2015 ~ 5 March, 2016 Pulmonary Aspergillosis with Brain Abscesses		Admission to the hospital 25 June ~ 18 July, 2016 Seizure		Admission to the hospital 22 August ~ 1 October, 2016 Navigator-assisted brain biopsy		OPD 16, February, 2017			
	1 Months	2 Months	4 Months	7 Months	9 Months	10 Months	15 Months			
12/5 Cyclophosphamide	12/12 Chest CT RUL abscess	12/24 Brain MRI hemorrhagic necrotic lesions, left frontotemporal and right temporoparietal	1/30 Chest CT CT-guided lung biopsy revealed the presence of fungal hyphi	3/4 Brain CT: resolution of left frontotemporal and right temporoparietal lesions	6/27 Brain MRI brain abscess at Rt temporal (14 x 12 mm) and Lt high frontal (17 x 15 mm, 8 x 7 mm)	8/23 Brain MRI brain abscess at right temporal (17.7 mm), left corona radiata (20.5 mm) and left high frontal subcortical (8 mm)	9/20 Brain CT of left frontotemporal and right temporoparietal lesions	2/16 Brain CT Residual lesions at right parietal (10 mm cystic lesion with hyperdense rim; 6mm/3.7 mm hyperdense nodules) and left frontal (15.7 mm cystic lesion with hyperdense rim		
Imaging & clinical progression										
Aspergillum Ag Index in blood; (BAL: Bronchoalveolar lavage)	12/14 0.2	12/17 > 7.18 (BAL)	12/23 2.6	2/22 0.55	6/28 1.88	7/4 2.73	7/11 1.94	8/5 1.72	9/22 0.6	2/14 0.12
Antibiotic progression	11/17~11/23 Levofloxacin 11/17~12/1 Cefpirome 12/2~12/13 cefoperazone /sulbactam	12/14~12/25 Meropenem + Sulbactam 12/22~1/3 Ganciclovir	12/26~2/6 Ceftazidime	6/25~9/2 Cefpirome	8/25~9/2 Meropenem					
Antifungus progression	12/16/2015 ~1/13/2016 Voriconazole iv	1/14 ~ 6/25 Voriconazole po	6/26 ~ 7/6 Voriconazole po 7/6 ~ 7/18 Voriconazole iv	7/19 ~ 8/18 Voriconazole po	8/22~9/6 Voriconazole iv 9/6~9/19 Amphotericin-B					9/19/2016 ~ 3/2 /2017 Posaconazole po

reveal chronic inflammation without identifying tumor growth or fungal elements. She was then maintained on oral voriconazole therapy until September 20, when CT image did not show further resolution (Figure 1H). The antifungal therapy was changed to oral posaconazole (600 mg per day) for 5 months, which achieved significant reduction of the brain lesions in the CT image on February 16, 2017 (Figure 1I). A blood *Aspergillus* antigen index became 0.12. The patient remained stable at the follow-up visit on July 4, 2017.

IPA is a well-known complication of immunosuppressive treatment for ANCA-associated vasculitis. The prolonged lymphocytopenia and ICU stay as well as corticosteroid and cytotoxic therapy might be the risk factors for systemic aspergillosis in our patient with p-ANCA vasculitis. Lymphocytopenia with depressed T-cell function may result in increased susceptibility to IPA [4]. The role of high-dose corticosteroid treatment should be taken into consideration as a risk factor for IPA, especially in critically ill patients and those with chronic obstructive pulmonary disease [5]. Cytotoxic chemotherapy has been regarded as a classical risk factor for invasive aspergillosis [6]; nonetheless, our patient only received one dose of intravenous cyclophosphamide (200 mg), so its significance was difficult to discern.

Since serious and opportunistic infections due to immunosuppressive agents and vasculitis are well known, improved recognition, diagnosis, and prevention of these infections have become important safety issues in these patients [7]. For example, less aggressive treatment without immunosuppressants for vasculitis might achieve clinical effectiveness and avoid opportunistic infections. Angiogenesis inhibitor but not an immunosuppressive agent could be a potential tool for the treatment of vasculitis [8,9].

Cerebral aspergillosis occurs primarily in patients with severe immunodeficiency, but can happen in a previously healthy or influenza-affected patient [10,11]. Cerebral aspergillosis accounts for 5-10% of all intracranial fungal pathology and may require anti-fungal therapy for 12-18 months [10]. Our case had experienced confirmed IPA and probably cerebral aspergillosis over a 15-month observation period with antifungal therapy (Table 1). *Aspergillus* galactomannan antigen assay might help early diagnosis and initiation of antifungal therapy. Posaconazole achieves successful salvage after prolonged voriconazole therapy [12].

In conclusion, diagnosis of invasive aspergillosis is challenging and treatment remains difficult. The gold standard diagnosis is made by specific histopatholo-

gy. The mortality rates are still high, so early therapy is mandatory.

Conflict of Interests

We declare no conflict of interest and financial support regarding this letter.

Ethics Statement

The above study has been granted exemption from review by the Institutional Review Board of Chi-Mei Medical Center (IRB Serial No. 10503-E03).

References

1. Akimoto T, Saito O, Inoue M, Nishino K, Onishi A, et al. (2007) Rapid formation of *Aspergillus* mycetoma in a patient receiving corticosteroid treatment. Serial radiographic observation over two months. *Intern Med* 46: 733-737.
2. Saito T, Shime N, Itoh K, Fujita N, Saito Y, et al. (2009) Disseminated aspergillosis following resolution of pneumocystis pneumonia with sustained elevation of β -glucan in an intensive care unit: A case report. *Infection* 37: 547-550.
3. Su T, Li HC, Chen M, Gao L, Zhou FD, et al. (2009) Invasive pulmonary aspergillosis in patients with antineutrophil cytoplasmic antibody associated vasculitis. *J Clin Rheumatol* 15: 380-382.
4. Fischer JJ, Walker DH (1979) Invasive pulmonary aspergillosis associated with influenza. *JAMA* 241: 1493-1494.
5. Kistemann T, Hüneburg H, Exner M, Vacata V, Engelhart S (2002) Role of increased environmental *Aspergillus* exposure for patients with chronic obstructive pulmonary disease (COPD) treated with corticosteroids in an intensive care unit. *Int J Hyg Environ Health* 204: 347-351.
6. Stevens DA, Melikian GL (2011) Aspergillosis in the 'non-immunocompromised' host. *Immunol Invest* 40: 751-766.
7. Isada CM (2012) Safety issues in vasculitis: Infections and immunizations in the immunosuppressed host. *Cleve Clin J Med* 79: S38-S45.
8. Brahn E, Lehman TJ, Peacock DJ, Tang C, Banquerigo ML (1999) Suppression of coronary vasculitis in a murine model of Kawasaki disease using an angiogenesis inhibitor. *Clin Immunol* 90: 147-151.
9. Maruotti N, Cantatore FP, Ribatti D (2014) Putative effects of potentially anti-angiogenic drugs in rheumatic diseases. *Eur J Clin Pharmacol* 70: 135-140.
10. Ellenbogen JR, Waqar M, Cooke RP, Javadpour M (2016) Management of granulomatous cerebral aspergillosis in immunocompetent adult patients: A review. *Br J Neurosurg* 30: 280-285.
11. Kim MJ, Kim MK, Kang CK, Jun KI, Bang JH, et al. (2009) A case of acute cerebral aspergillosis complicating influenza A/H1N1pdm 2009. *Infect Chemother* 45: 225-229.
12. Heinz WJ, Egerer G, Lellek H, Boehme A, Greiner J (2013) Posaconazole after previous antifungal therapy with voriconazole for therapy of invasive aspergillus disease, a retrospective analysis. *Mycoses* 56: 304-310.