



CASE REPORT

Salbutamol Inhalation Could Induce Fatal Multi-Vessel Coronary Artery Spasm in COPD Patients

Li Jiwu¹, Zhang Ping^{2*} and Shao Liang^{3*}

¹Department of Cardiology, The Second Affiliated Hospital of Wenzhou Medical University, Wenzhou, Zhejiang Province, China

²Department of Neurology, Jiangxi Provincial People's Hospital, People's Republic of China

³Department of Cardiology, Jiangxi Provincial People's Hospital, People's Republic of China

*Corresponding author: Shao Liang, Department of Cardiology, Jiangxi Provincial People's Hospital, No. 92 Aiguo Road, Donghu District, Nanchang, 330006, Jiangxi, People's Republic of China, E-mail: shaoliang021224@hotmail.com;

Zhang Ping, Department of Neurology, Jiangxi Provincial People's Hospital, No. 92 Aiguo Road, Donghu District, Nanchang, 330006, Jiangxi, People's Republic of China, E-mail: zhangkiki520@126.com



Abstract

Coronary artery spasm is a sudden and intense vasoconstriction of single-or multi-vessel coronary artery. It may be triggered by several acute stress. This case reports 72-year-old male with salbutamol inhalation suffer fatal multi-vessel coronary artery spasm. After intracoronary administration of nitroglycerin, coronary artery spasm was relieved. It reminds us to be cautious of β -agonist administration in respiratory patients with coronary artery spasm risk.

Keywords

Coronary artery spasm, Salbutamol inhalation, Chronic obstructive pulmonary disease

Introduction

Coronary artery spasm (CAS) is one of the important functional cardiac disorders referred to a sudden and intense vasoconstriction of single-or multi-vessel coronary artery [1,2]. And it is well known to be associated to stable angina, acute coronary syndrome, even cardiac sudden death [3-5]. However, coronary angiography also showed that CAS not only occurred at the site of a stenosis (either minor or severe) but also in angiographically normal coronary arteries [5]. Although the causes and the mechanisms of CAS are still not revealed, inflammation, oxidative stress and autonomic nervous system have catch some truth [6-8].

Case Report

In our report, a 72-year-old male, a chronic smoker

with history of hypertension and COPD (chronic obstructive pulmonary disease), firstly presented with shorten of breath in Respiratory Department by history and CT image diagnosis as shown in Figure 1. After accepting salbutamol inhalation therapy, patient had a sudden chest pain, progressive low blood press and shock. There was showed a fast sinus rhythm with marked depression of ST-T segment in V2-V5 chest leads by electrocardiogram (ECG) (Figure 2A). Cardiac troponin I, creatine kinase and lactate dehydrogenase level were significantly elevated confirming myocardial injury and death. Patient was received urgently oral treatment of aspirin 300 mg, clopidrogel 600 mg, and atorvastatin 40 mg before CAG (coronary angiography) operation. Emergency CAG showed widely spasm of left anterior descending (LAD), left circumflex (CIRC) arteries and right coronary artery (RCA) as shown in Figure 3. After intracoronary administration of nitroglycerin, coronary artery spasm was relieved. LAD, CIRC and RCA were appeared bigger in calibre and were non-obstructive in Figure 3.

Discussion

Inflammation and autonomic nervous system play some roles in coronary artery spasm. Some inflammatory stimulus, such as interleukin-1 β , serotonin and histamine could induce vascular smooth muscle cells hyperreactivity which is the key abnormality responsible for CAS [9-12]. Also, inflammation is a demonstrated pathophysiological basis of COPD [13]. Interleukin-1 β ,



Citation: Jiwu L, Ping Z, Liang S (2018) Salbutamol Inhalation Could Induce Fatal Multi-Vessel Coronary Artery Spasm in COPD Patients. J Geriatr Med Gerontol 4:050. doi.org/10.23937/2469-5858/1510050

Accepted: June 14, 2018; **Published:** June 16, 2018

Copyright: © 2018 Jiwu L, et al. This is an open-access article distributed under the terms of the Creative Commons Attribution License, which permits unrestricted use, distribution, and reproduction in any medium, provided the original author and source are credited.

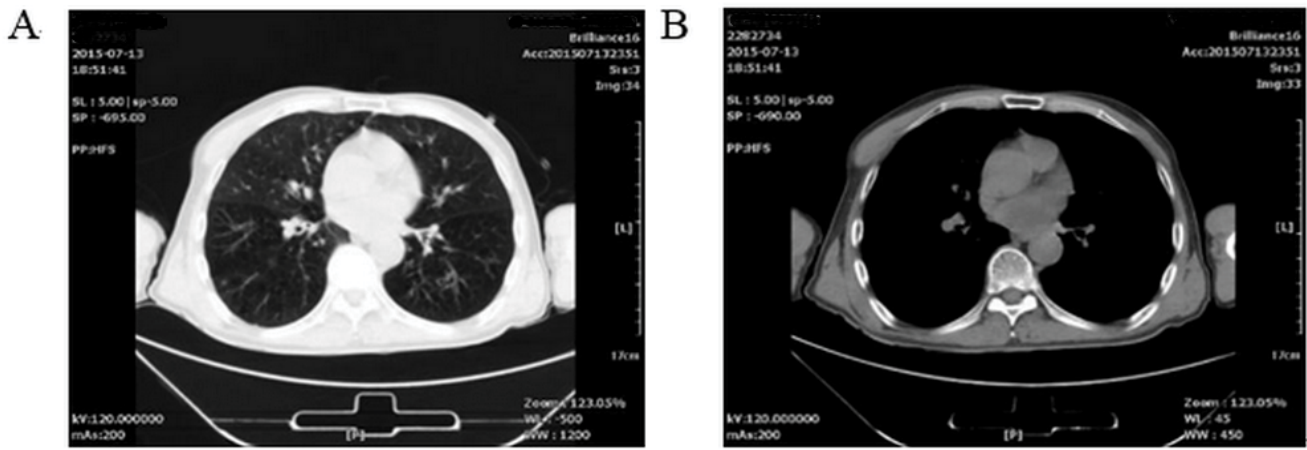
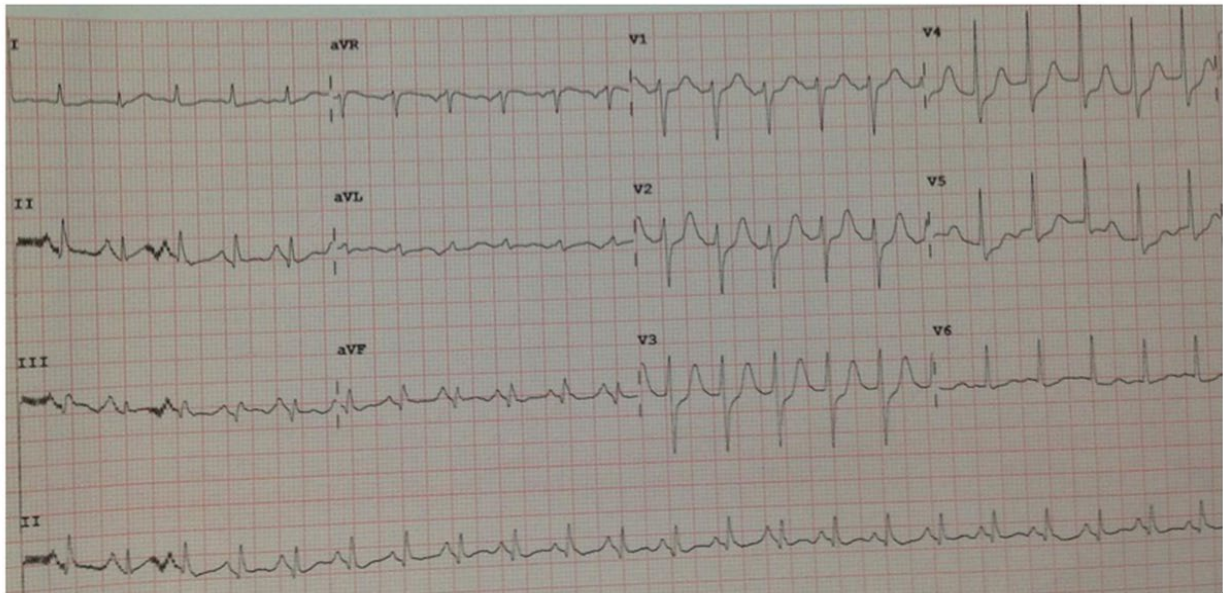


Figure 1: Patient presented lung infection and COPD symptom signal by CT screening.

A



B

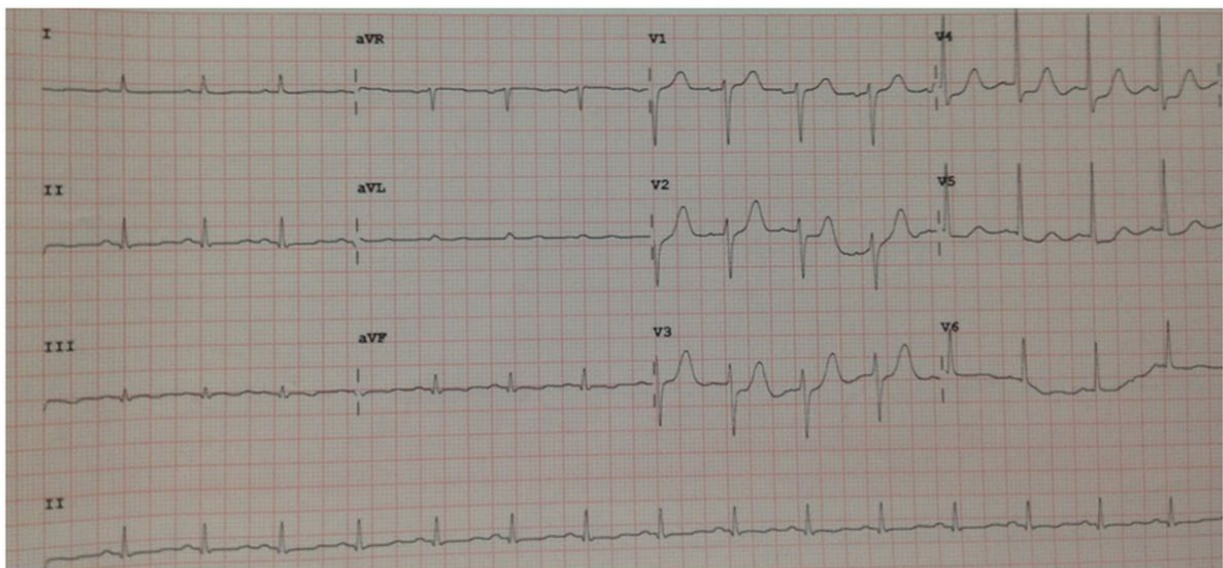
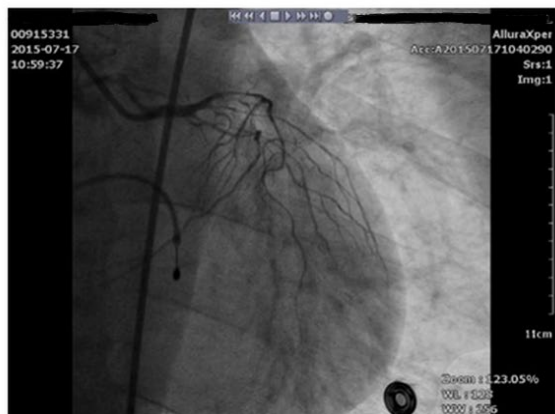
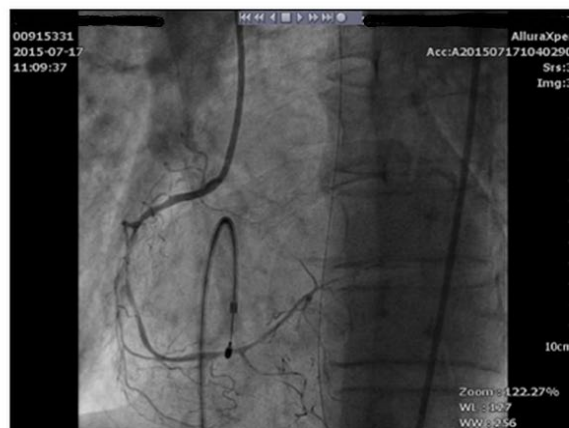

Figure 2: Patient's ECG change. A) Patient presented chest pain before PCI operation; B) Patient's chest pain was relieved after nitroglycerin injection.

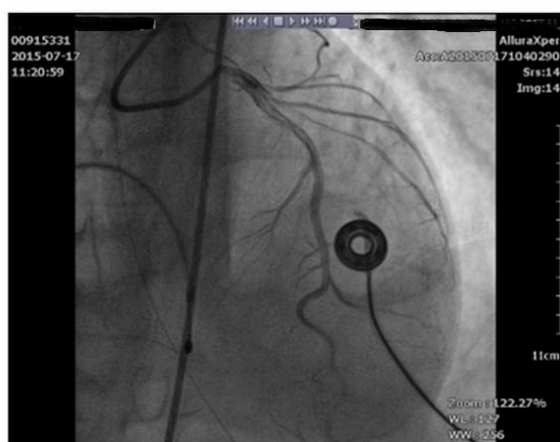
A1



B1



A2



B2

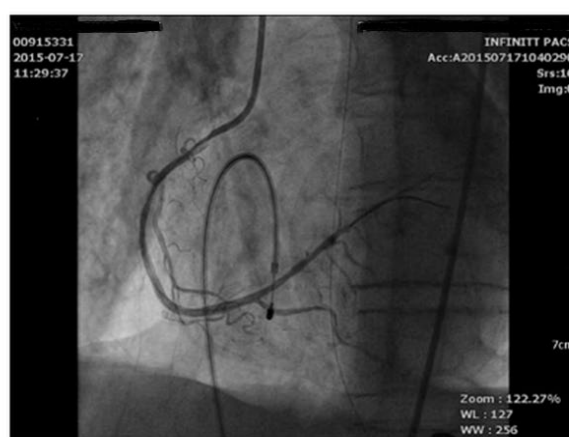


Figure 3: Coronary angiographies before and after intracoronary administration of nitroglycerin. Widely coronary artery spasm presented before intracoronary nitroglycerin injection in A1 and B1. After intracoronary nitroglycerin injection, coronary artery spasm was relieved in A2 and B2.

serotonin and histamine show a high levels in COPD patients [14,15].

The adverse effects of salbutamol (β -agonist reagent) are tachycardia, arrhythmia, and even myocardial ischemia [16]. But the effect of autonomic nervous system on CAS is complex. β -blockers may exacerbate angina attacks in patients with variant angina [17].

Conclusion

In summary, CAS is at the site of coronary stenosis or in angiographically normal coronary arteries. It may be triggered by emotional stress, cold exposure, and stimulant drugs such as amphetamines and cocaine. But it is rare a case of multi-vessel coronary artery spasm induced by β -agonist inhalation. As illustrated by our case, it must be cautious of β -agonist administration in respiratory patients with coronary artery spasm risk.

Declaration of Conflicting Interests

The authors declare no potential conflicts of interest with respect to the research, authorship, and/or publication of this article.

Conflict of Interest

The authors state no conflict of interest.

Acknowledgement

The authors disclose receipt of the following financial support for the research, authorship, and/or publication of this article: Supported by the National Natural Science Foundation of China (Grant No. 81300115) to Liang Shao.

References

- Maseri A, Beltrame JF, Shimokawa H (2009) Role of coronary vasoconstriction in ischemic heart disease and search for novel therapeutic targets. *Circ J* 73: 394-403.
- Lanza GA, Careri G, Crea F (2011) Mechanisms of coronary artery spasm. *Circulation* 124: 1774-1782.
- Ong P, Athanasiadis A, Borgulya G, Voehringer M, Sechtem U (2011) 3-year follow-up of patients with coronary artery spasm as cause of acute coronary syndrome: The CAS-PAR (coronary artery spasm in patients with acute coronary syndrome) study follow-up. *J Am Coll Cardiol* 57: 147-152.
- Hamm CW, Bassand JP, Agewall S, Bax J, Boersma E, et al. (2011) ESC guidelines for the management of acute coronary syndromes in patients presenting without persistent

- ST-segment elevation: The Task Force for the management of acute coronary syndromes (ACS) in patients presenting without persistent ST-segment elevation of the European Society of Cardiology (ESC). *Eur Heart J* 32: 2999-3054.
5. Romagnoli E, Lanza GA (2007) Acute myocardial infarction with normal coronary arteries: Role of coronary artery spasm and arrhythmic complications. *Int J Cardiol* 117: 3-5.
 6. Katayama N, Nakao K, Horiuchi K, Kasanuki H, Honda T (2005) Disease activities and serum C-reactive protein levels in patients with vasospastic angina pectoris. *J Cardiol* 46: 63-70.
 7. Park K, Gross M, Lee DH, Holvoet P, Himes JH, et al. (2009) Oxidative stress and insulin resistance: The coronary artery risk development in young adults study. *Diabetes Care* 32: 1302-1307.
 8. Yasue H, Horio Y, Nakamura N, Fujii H, Imoto N, et al. (1986) Induction of coronary artery spasm by acetylcholine in patients with variant angina: Possible role of the parasympathetic nervous system in the pathogenesis of coronary artery spasm. *Circulation* 74: 955-963.
 9. Kaski JC, Tousoulis D, Gavrielides S, McFadden E, Galassi AR, et al. (1991) Comparison of epicardial coronary artery tone and reactivity in Prinzmetal's variant angina and chronic stable angina pectoris. *J Am Coll Cardiol* 17: 1058-1062.
 10. Bertrand ME, LaBlanche JM, Tilmant PY, Thieuleux FA, Delforge MR, et al. (1982) Frequency of provoked coronary arterial spasm in 1089 consecutive patients undergoing coronary angiography. *Circulation* 65: 1299-1306.
 11. Kaski JC, Maseri A, Vejar M, Crea F, Hackett D (1989) Spontaneous coronary artery spasm in variant angina is caused by a local hyperreactivity to a generalized constrictor stimulus. *J Am Coll Cardiol* 14: 1456-1463.
 12. Fukumoto Y, Shimokawa H, Ito A, Kadokami T, Yonemitsu Y, et al. (1997) Inflammatory cytokines cause coronary arteriosclerosis-like changes and alterations in the smooth muscle phenotypes in pigs. *J Cardiovasc Pharmacol* 29: 222-231.
 13. Mehta S, Helmersen D, Provencher S, Hirani N, Rubens FD, et al. (2010) Diagnostic evaluation and management of chronic thromboembolic pulmonary hypertension: A clinical practice guideline. *Can Respir J* 17: 301-334.
 14. Wang YS, Liu L, Xu XY, Wang JL, Zhou H, et al. (2015) Association of interleukin-1 β -511C/T promoter polymorphism with COPD risk: A meta-analysis. *Genet Mol Res* 14: 4477-4484.
 15. Hospers JJ, Postma DS, Rijcken B, Weiss ST, Schouten JP (2000) Histamine airway hyper-responsiveness and mortality from chronic obstructive pulmonary disease: A cohort study. *Lancet* 356: 1313-1317.
 16. (2008) "3.1.1.1 Selective beta2 agonists - side effects". *British National Formulary (57thedn)*, London: BMJ Publishing Group Ltd and Royal Pharmaceutical Society Publishing.
 17. Robertson RM, Wood AJ, Vaughn WK, Robertson D (1982) Exacerbation of vasotonic angina pectoris by propranolol. *Circulation* 65: 281-285.