



## CASE REPORT

# Duodenal Lipoma Causing Recurrent Duodenal Obstruction: A Rare Case, Managed Surgically

Sachin Jain\*, Neeraj Goel and Amit Kumar

Department of GI Surgery, Dharamshila Narayana Super Speciality Hospital, India

\*Corresponding author: Sachin Jain, Associate Consultant, Department of GI Surgery, Dharamshila Narayana Super speciality Hospital, Delhi, India



## Abstract

Duodenal lipomas are rare gastrointestinal (GI) tumours. Due to their rarity and the uncertainty of their presentation, as the majority of these lesions are asymptomatic, these lesions are occasionally overlooked. Most patients experience symptoms in lesions > 2 cm in diameter. These lesions can present with GI haemorrhage, bowel obstruction and abdominal pain or discomfort. Symptomatic duodenal lipoma requires excision. Endoscopic excision is the suggested course of treatment. Endoscopic excision for big or sessile lesions may be technically challenging and increase the risk of bleeding and perforation. Thus, surgical excision would be the recommended method in such circumstances. We report a case of duodenal lipoma causing recurrent duodenal obstruction requiring surgical management.

## Keywords

Duodenal lipoma, Duodenal obstruction, Surgery, Giant duodenal polyp

## Introduction

Duodenal lipomas are rare gastrointestinal (GI) tumours, most frequently occurring in the second part of duodenum. They are mostly asymptomatic and found incidentally on endoscopy. When symptomatic, they can also present with GI haemorrhage, bowel obstruction and pain or discomfort in the abdomen. Symptomatic duodenal lipoma requires excision. If the lesion is polypoid and of manageable size, endoscopic excision is the suggested course of treatment. Endoscopic excision for big or sessile lesions may be technically challenging and increase the risk of bleeding and perforation. Thus, surgical excision would be the recommended method in such circumstances.

## Case Report

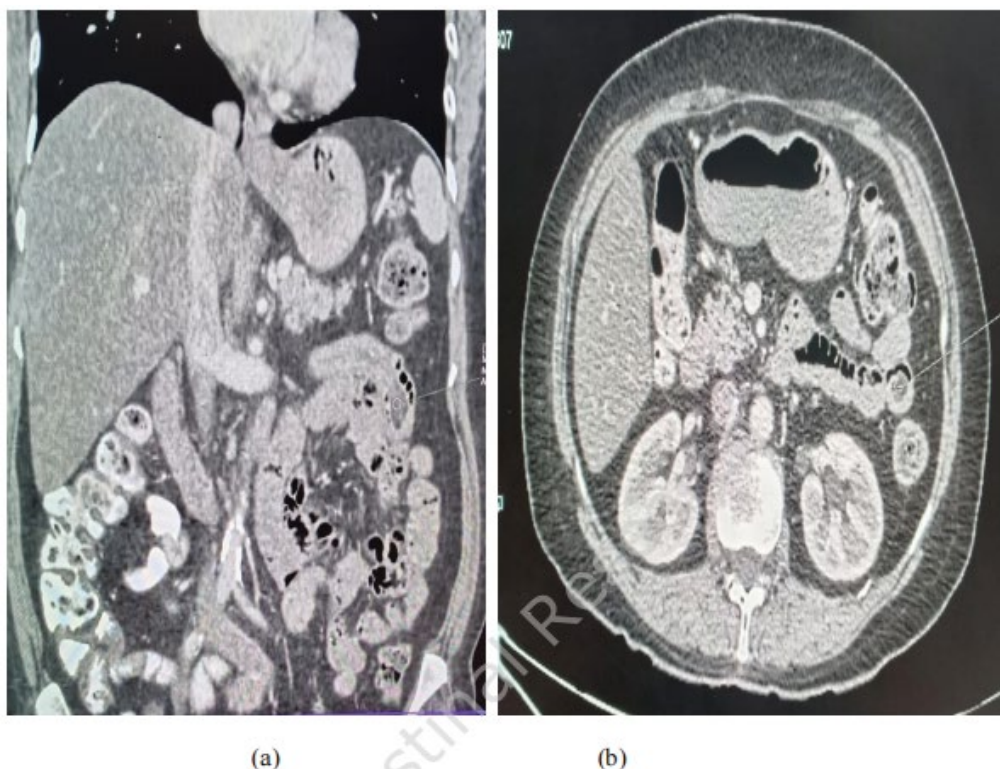
A 69-year-old lady, presented to emergency department, with complaints of recurrent abdominal pain, located in epigastric and central abdomen, non-radiating, associated with bilious vomiting since few weeks. She had past history of laparoscopic cholecystectomy done for symptomatic gall stones, a few years back. She had history of left knee osteoarthritis and sciatica for few years and was taking occasional pain killers. She was a known case of diabetes and hypertension. Clinical examination was unremarkable. No abdominal tenderness or distension. She was evaluated with USG abdomen which was suggestive of grade 2 fatty liver. CECT abdomen was done which showed a subcentrimetric fat attenuation lesion in the lumen of proximal jejunum (10 mm size) with linear enhancing area (length 10 cm), arising from duodenojejunal junction - ? pedunculated lipomatous or fibrovascular polyp (Figure 1).

She underwent UGI endoscopy which revealed mild antral gastritis and duodenitis with elongated pedunculated polyp arising from 3<sup>rd</sup> or 4<sup>th</sup> part of duodenum and filling duodenal lumen (Figure 2).

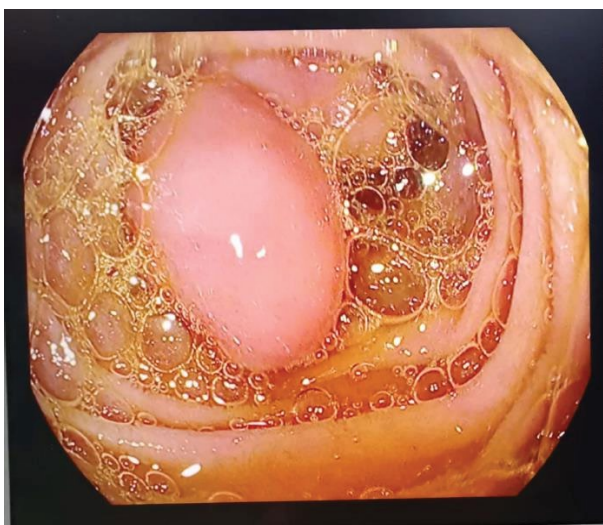Endoscopic removal of the polyp could not be done in view of unfavourable polyp location. She was taken for surgery in view of recurrent duodenal obstruction.

Intraoperatively, an elongated polyp was palpable at DJ flexure. Enterotomy was done at proximal jejunum and polyp was brought out for examination (Figure 3).

Base of polyp was arising from 4<sup>th</sup> part of duodenum (Figure 4).



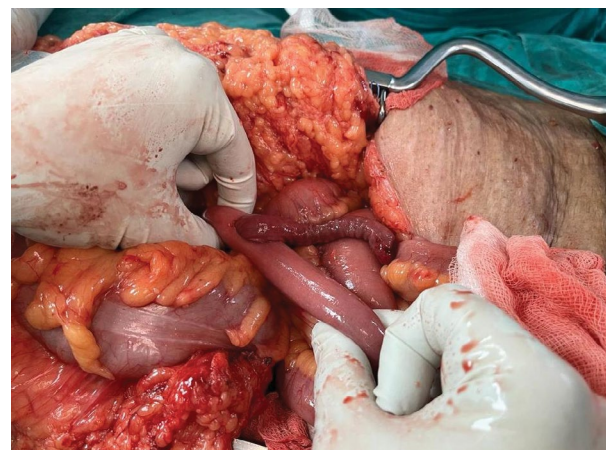
**Figure 1:** Coronal (a) and axial (b) view of CECT abdomen showing fat attenuation polyp near DJ flexure.



**Figure 2:** Endoscopic view of the 4<sup>th</sup> part of the duodenum showing a pedunculated mass with smooth mucosa, filling duodenal lumen.

Enlarged mesenteric lymph nodes were present in proximal jejunal mesentery. Duodenojejunal resection (D3, D4, proximal jejunum) + duodeno-jejunal anastomosis + feeding jejunostomy was done (Figure 5).

FJ trial was started on postoperative day 1 and gradually increased to full FJ feeds which she tolerated well. NG tube was removed on postop day 4 and she was allowed oral liquids, gradually increased to soft diet by postop day 6. Abdominal drain was removed on postop day 6 and patient was discharged on postop day 6.



**Figure 3:** Showing enterotomy near DJ flexure to examine base of polyp.

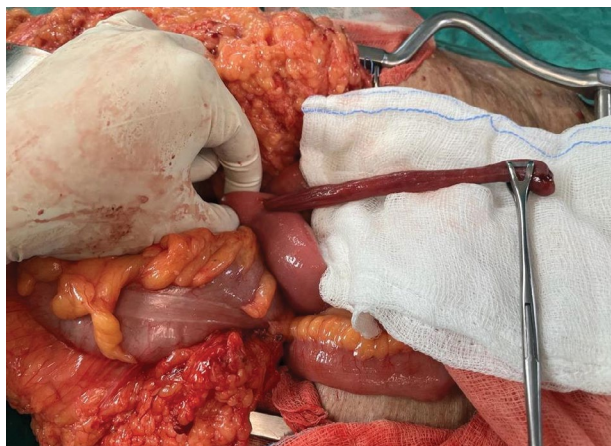
Final histopathology of the specimen was duodenal polypoid lipoma - 7.5 × 1.5 × 1 cm (Figure 6 and Figure 7).

## Discussion

Duodenal lipomas are rare gastrointestinal (GI) tumours and make up 4% of all GI lipomas. The large intestine (64%), small intestine (26%), duodenum (4%), stomach (3%), and oesophagus (2%), are the GI tract's most frequent locations for lipomas [1]. Although duodenal lipoma can develop in any part of the duodenum, they most frequently do so in the second part [2]. They are mostly asymptomatic and found incidentally on endoscopy. When symptomatic,



they can also present with GI haemorrhage, bowel obstruction and pain or discomfort in the abdomen. The median age at presentation was 62.7 years, with slight female preponderance [3].

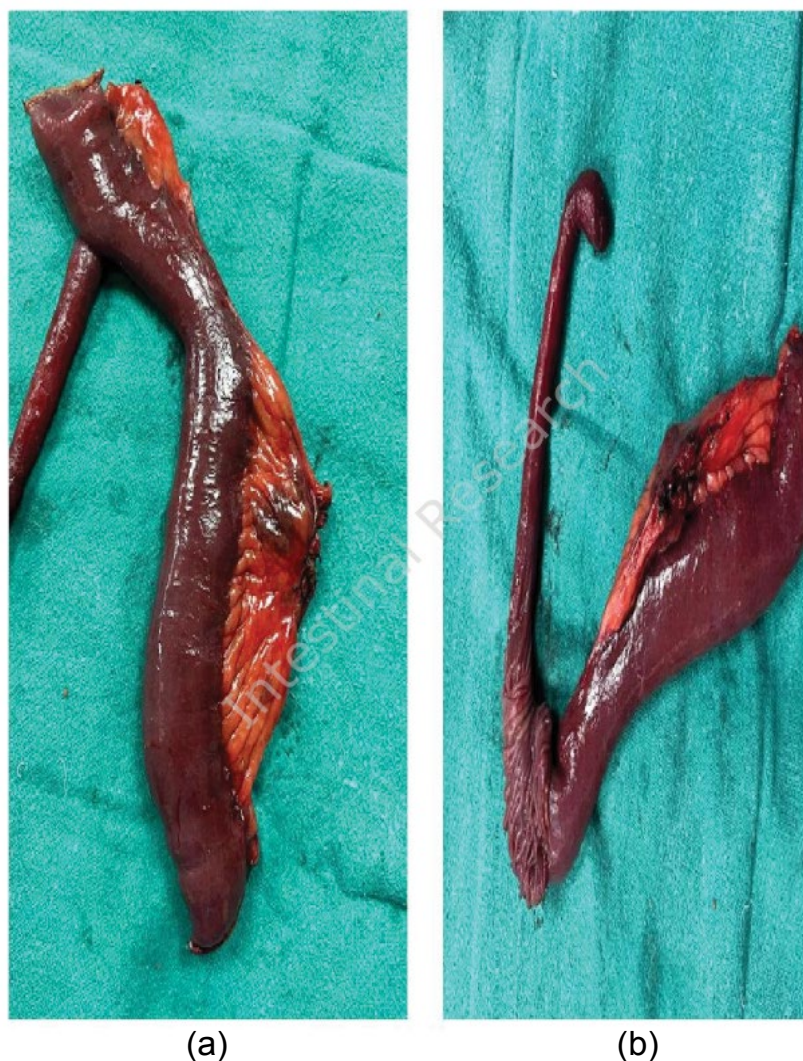

**Figure 4:** Showing base of polyp arising from 4<sup>th</sup> part of duodenum.

Duodenal lipomas can be sessile or pedunculated. In majority of cases, they are pedunculated.

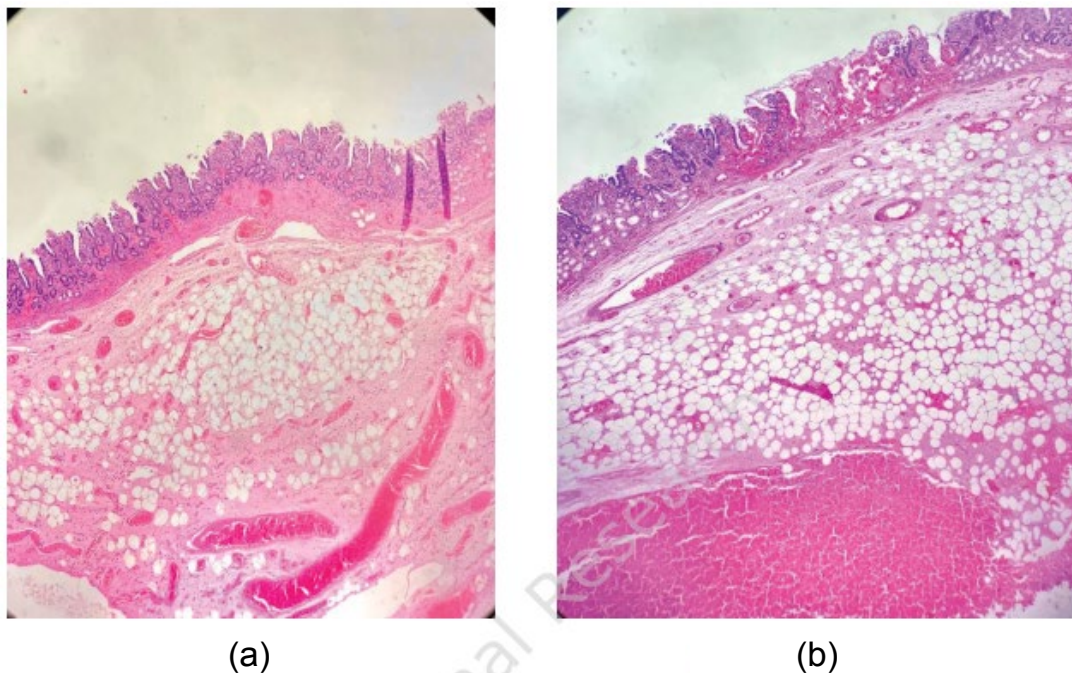
Uncertainty surrounds the pathophysiology of duodenal lipomas; it could result from inflammatory stimulation, fat accumulation, or aberrant gonadal hormone release from the anterior pituitary [4]. Due to their rarity and the uncertainty of their presentations -the majority of tiny lesions are asymptomatic- these lesions are occasionally overlooked. 80% of patients experience symptoms in lesions larger than 2 cm in diameter [5].

With 46.4% of cases, melena is the most frequent presenting symptom, followed by postprandial fullness and stomach pain. GI haemorrhage, intestinal obstruction, intussusception, anaemia, and anaemia are other manifestations that have been documented in the literature [6].

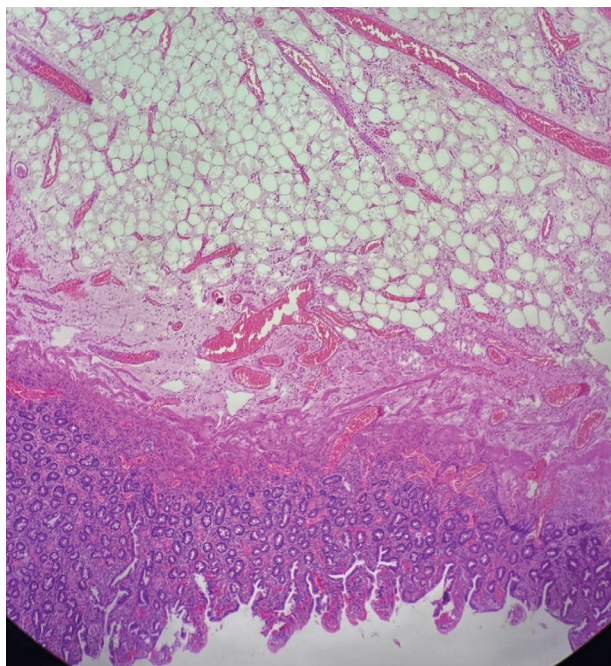


**Figure 5:** Operative specimen showing elongated pedunculated/stalked polyp arising from 4th part of duodenum. (a) Gross specimen (b) Duodenum cut open to reveal polyp base.





**Figure 6:** Duodenal Lipoma- Microphotograph showing mature adipocytes and congested vessels in the submucosa of the duodenal wall (H and E- 40X).



**Figure 7:** Duodenal Lipoma- Microphotograph showing mature adipocytes and congested vessels in the submucosa (H and E 100 X).

Computed tomography (CT), shows lipoma as a low density fat attenuation lesion. These lesions can also be precisely detected by magnetic resonance (MR) imaging where the lipoma shows up as hyperintense on T1-weighted MR images and reduction of signal intensity on T2-weighted imaging and loss of signal intensity on T1- and T2-weighted fat-suppressed images [7]. The diagnosis of duodenal lipomas can benefit greatly from EUS. All eight lesions in the eight patients in Chen, et

al.'s case series with a pathological diagnosis of DLs were described as intense homogeneous hyperechoic lesions [8]. Additionally, EUS can offer important information about depth and invasion.

Symptomatic duodenal lipomas require excision [9]. If the lesion is polypoid and of manageable size, endoscopic excision is the suggested course of treatment [10,11]. Endoscopic excision for big or sessile lesions may be technically challenging and increase the risk of bleeding and perforation. Thus, surgical excision would be the recommended method in such circumstances.

### Conclusion

Intestinal obstruction due to duodenal lipoma is a rare occurrence, especially occurring in large duodenal lipomas. These require excision, either endoscopic or surgical. Large or sessile lesions pose a risk of bleeding and perforation, for endoscopic removal. Surgical excision is prudent in such scenarios.

### Sources of Support

Nil.

### Statement of Equal Authors' Contribution

All authors contributed equally for this work.

### References

1. Mayo CW, Pagtaluman RJG, Brown DJ (1963) Lipoma of the alimentary tract. *Surgery* 53: 598-603.
2. Kadaba R, Bowers KA, Wijesuriya N, Preston SL, Bray GB, et al. (2011) An unusual cause of gastrointestinal bleeding: duodenal lipoma. *Case Rep Gastroenterol* 135: 183-188.
3. Pei MW, Hu MR, Chen WB, Qin C (2017) Diagnosis and

- treatment of duodenal lipoma: A systematic review and a case report. *J Clin Diagn Res* 11: PE01-PE05.
4. Hu ZW, Liang P, Li ZL, Li YA, Li ML, et al. (2021) Diagnostic value and potential clinical significance of duodenal lipoma based on computed tomography imaging data. *Medicine (Baltimore)* 100: e26944.
  5. Blanchet MC, Arnal E, Paparel P, Grima F, Voiglio EJ, et al. (2003) Obstructive duodenal lipoma successfully treated by endoscopic polypectomy. *Gastrointest Endosc* 58: 938-939.
  6. Mousa MI, Al Ghamdi SS, Alsolmi AA, Fakhri AF (2023) Duodenal Lipoma As Upper Gastrointestinal Bleeding Presentation: Case Report and Review of the Literature. *Cureus* 15: e33996.
  7. Domenech-Ximenes B, Juanpere S, Serra I, Codina J, Maroto A (2020) Duodenal tumors on cross-sectional imaging with emphasis on multidetector computed tomography: a pictorial review. *Diagn Interv Radiol* 26: 193-199.
  8. Chen HT, Xu GQ, Wang LJ, Chen YP, Li YM (2011) Sonographic features of duodenal lipomas in eight clinicopathologically diagnosed patients. *World J Gastroenterol* 17: 2855-2859.
  9. Parmar AK, Bibyan M, Khandelwal R, Reddy PK (2013) Laparoscopic management of a large duodenal lipoma presented as gastric outlet obstruction. *JLS* 17: 459-462.
  10. Yu HG, Ding YM, Tan S, Luo HS, Yu JP (2007) A safe and efficient strategy for endoscopic resection of large, gastrointestinal lipoma. *Surg Endosc* 21: 265-269.
  11. Zirpe D, Wani M, Tiwari P, Ramaswamy PK, Kumar RP (2016) Duodenal Lipomatosis as a Curious Cause of Upper Gastrointestinal Bleed: A Report with Review of Literature. *J Clin Diagn Res* 10: PE01-PE04.