



CASE STUDY

Manual Therapy and Upper Quarter Training in an Adolescent Quarterback with Chronic Clinically Suspected Thoracic Outlet Syndrome: A Case Report with 1-Year Follow Up

Denny B^{1,2*} and Brismée JM^{2,3}

¹Sports Medicine & Physical Therapy- Marble Falls, USA

²International Academy of Orthopedic Medicine-Anchorage, USA

³Center for Rehabilitation Research, Texas Tech University Health Sciences Center, USA

*Corresponding author: Denny B, Sports Medicine & Physical Therapy- Marble Falls; International Academy of Orthopedic Medicine-Anchorage, P.O. Box 249, Iredell, Texas 76649, USA



Abstract

Background: The brachial plexus neurovascular bundle has been described as a pain generating entity in the upper quarter. Many factors contribute to neurovascular irritability, not least of which shoulder girdle mobility dysfunctions, particularly in the throwing athlete.

Methods: This case study describes clinical identification of upper quarter impairments contributing to a suspected disputed neurogenic thoracic Outlet Syndrome (TOS) in a high school quarterback. Specific clinical examination using provocation, mobility, upper quarter dynamic control, and functional outcome measures led to directed interventions.

Results: Reported symptom resolution began after 3 sessions and functional control was restored by the 10th session. Improvements remained at 1-year follow up.

Conclusion: While clinical causation cannot be inferred from a single subject case report, these outcomes are indicative of how shoulder girdle mobility and dynamic control impairments may contribute to brachial plexus irritability in a throwing athlete. Moreover, these specific interventions may be useful in other patients with similar impairments.

Keywords

Brachialgia, Elevated rib, Shoulder girdle mobility impairment

subclavian artery, vein, and brachiocephalic vein through three primary spaces [1]. Neurogenic Thoracic Outlet Syndrome (nTOS) is subclassified as true and disputed. The primary is the presence of true neurogenic deficits in true nTOS rather than subjective symptoms without objectifiable neurogenic deficits in disputed nTOS [2]. This lack of true objective findings and variable individual clinical TOS tests sensitivity and specificity has resulted in TOS being a controversial diagnosis [3,4]. To further complicate matters, this clinical entity has been described contributing to double crush phenomenon in upper extremity peripheral neuralgias and with cervical nerve roots [5].

Contact trauma to the brachial plexus during football has been reported [6] including posterior clavicular dislocation [7]. Brachial plexus neuropraxia has been described in football players due to neural tensioning events whereby the cervical spine bends opposite the shoulder girdle [8], however to the authors' knowledge no studies describe nTOS resulting from shoulder girdle mobility impairments and 1st rib elevation secondary to football contact trauma. This case report describes clinical identification and management of a suspected disputed nTOS in an adolescent football quarterback. It aims to highlight shoulder girdle mobility impairments may contribute to thoracic outlet irritability. Moreover, specific manual therapy and upper quarter training may be employed for successful management.

Background

Thoracic outlet syndrome describes a neurovascular bundle compression involving the brachial plexus,



Citation: Denny B, Brismée JM (2022) Manual Therapy and Upper Quarter Training in an Adolescent Quarterback with Chronic Clinically Suspected Thoracic Outlet Syndrome: A Case Report with 1-Year Follow Up. Int J Sports Exerc Med 8:217. doi.org/10.23937/2469-5718/1510217

Accepted: March 28, 2022; **Published:** March 30, 2022

Copyright: © 2022 Denny B, et al. This is an open-access article distributed under the terms of the Creative Commons Attribution License, which permits unrestricted use, distribution, and reproduction in any medium, provided the original author and source are credited.

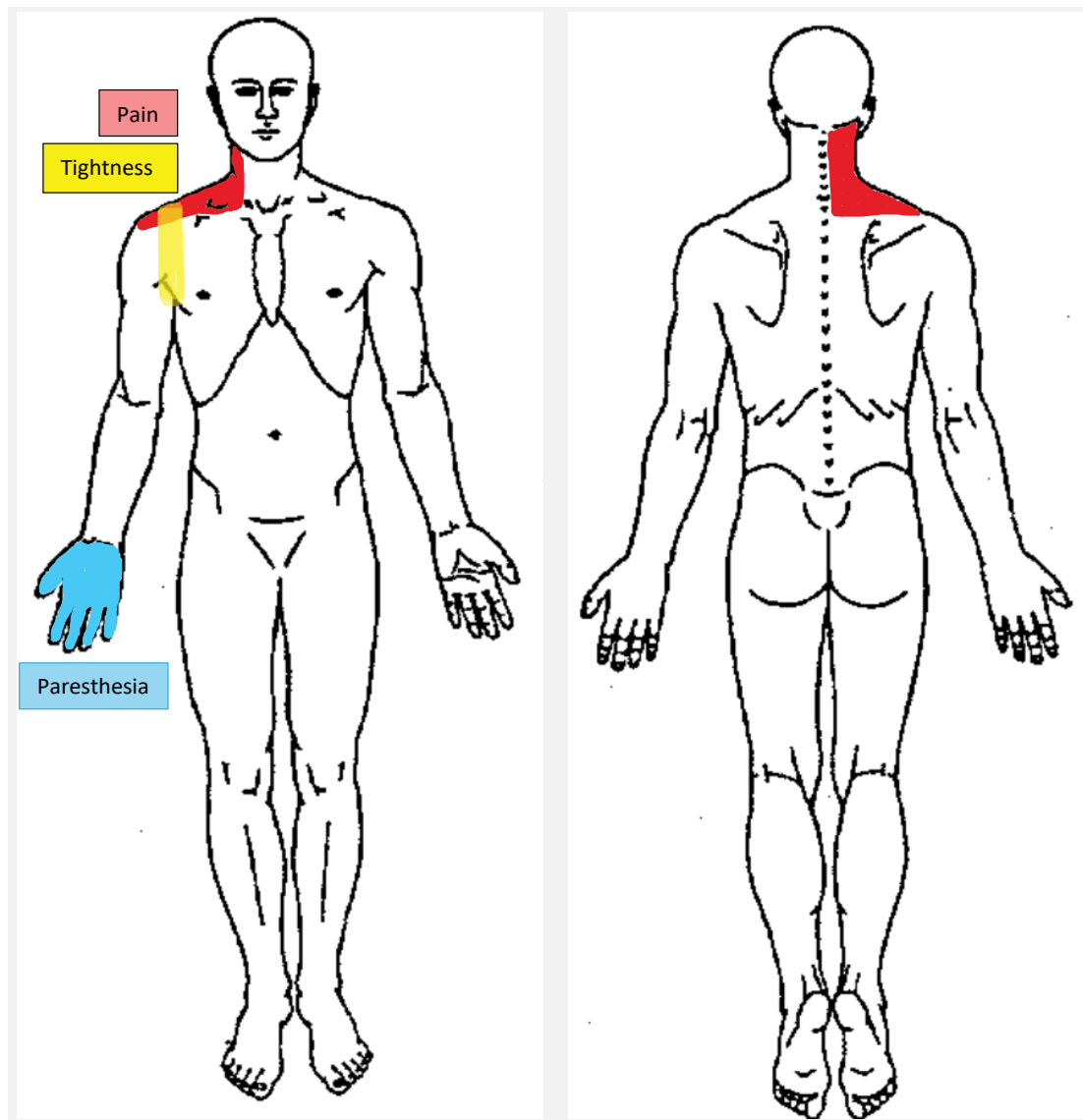


Figure 1: Pain Diagram indicating location of pain and paresthesia.

Case Presentation

Patient history

The 17-year-old, right-handed male American football quarterback voluntarily consented to participate for this case report. His symptoms included a 1-year history of pain, stiffness, and elevation intolerance after a contact trauma from landing on his right shoulder. His medical history was unremarkable. He took ibuprofen as needed, and reported generally good health.

He described multiple painful areas (Figure 1) rating between 2/10 at best and 6/10 at worst on the numerical pain rating scale. His right-hand paresthesia was associated with overhead fatigue, hand pallor in elevated positions, and nocturnal paresthesia that consistently disturbed his sleep. Aggravating factors included reaching overhead and throwing. His primary functional limit pertained to diminished football throwing capability. His goals included symptom reduction, sleep improvement, increased overhead tolerance, and improved ability to throw.

Functional outcome measure

The *Disabilities of the Arm, Shoulder, and Hand (DASH)* questionnaire was designed to assess functional upper extremity disabilities in people with upper extremity problems. His initial DASH score was 12.9 (Raw score: 44/29 questions). The minimally clinically important difference unspecified shoulder disorder it may range between 3.9-15 [9].

Clinical examination

Inspection: Observation revealed a mild forward head posture, greater anterior tipping and medial rotation right scapula compared to his left in resting.

Shoulder examination: Cervical motions were unlimited and pain free with unremarkable myotome, dermatome, reflex, and segmental mobility tests. Passive glenohumeral mobility, active elevation, and manual muscle testing revealed mild rotator cuff strength deficits bilaterally.

Thoracic outlet examination: Thoracic outlet

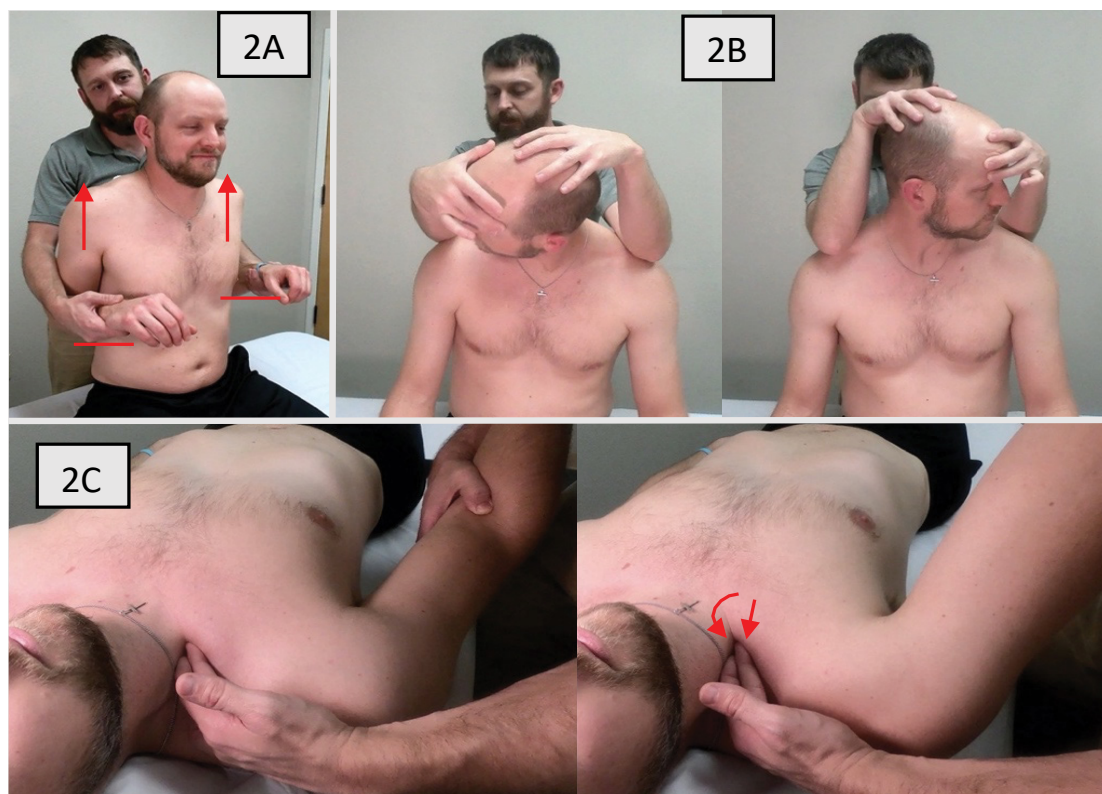


Figure 2: Thoracic outlet tests. (A) **Cyriax Release Maneuver:** The examiner passively elevates the shoulder girdle for up to 3 minutes. Paresthesia reproduction indicates a release phenomenon [2]; (B) **Cervical Rotation Lateral Flexion:** The examiner passively rotates ipsilaterally and laterally flexes contralaterally. Marked limitation with harder end feel indicated an elevated 1st rib [2,23]; (C) **Helfett's Clavicle Test:** The examiner palpates premature proximal clavicular dorsal movement during passive arm elevation [12].

Table 1: Clinical assessment.

Assessment	
Pain Generator	Right brachial plexus
Clinical Syndrome	Disputed neurogenic thoracic outlet syndrome
Tissue Dysfunctions	Elevated and stiff 1 st rib Stiff acromioclavicular joint Stiff sternoclavicular joint
Sensorimotor Dysfunctions	Diminished deep cervical endurance Scapular dyskinesia Diminished posterior rotator cuff strength
Functional Deficits	Prolonged overhead positioning Throwing

examination includes provocation and container tests for rib position and shoulder girdle mobility [2]. Elevated Arm Stress Test (EAST) provoked right hand pallor in less than 10 seconds and familiar paresthesia at 20 seconds. His median nerve biased Upper Limb Neural Tension Test (ULNTT) was painfully limited at 30° elbow flexion. Cyriax Release Maneuver provoked his familiar right-hand paresthesia at 22 seconds and his cervical rotation lateral flexion test revealed elevated right 1st rib. Elevation chain mobility tests revealed hypomobile clavicular mobility (Helfett's) at the acromioclavicular and sternoclavicular joint resulting in premature clavicular rotation with passive & active arm elevation (Figure 2).

Upper quarter dynamic control: Deep neck flexor endurance measured 20-seconds, below normative 40

seconds for healthy males [10]. Left Scapulothoracic upward rotation during active arm elevation was 60° compared to his right, 45°. Moreover, scapular dyskinesias observed were ventral tipping and medial rotation.

Interpretation

The clinical problem list and assessment are summarized in Table 1. Hand pallor with elevation frequently occurs with arterial TOS secondary to subclavian artery compression, it may occur because sympathetic overactivity as these fibers travel along the lower brachial plexus trunk [11]. These symptoms were most aggravated with upper extremity elevation and his hand paresthesia woke him up nightly. Cervical and shoulder clinical examinations failed to provoke his familiar symptoms. The most provocative testing

included the elevated arm stress test (84% sensitivity, 30% specificity) [4], Cyriax Release (specificity 97.4% with 1-minute hold) [12] and median nerve biased ULNTT. Despite the troubled validity and high false positive rates of individual TOS tests a cluster of 2 or more provocative tests achieves a 90% sensitivity [2,4]. Thus a 10% chance of a false negative. Specifically, the patient had two provocative TOS tests, and a right median ULNTT. Moreover, he presented with acromioclavicular and sternoclavicular mobility deficits, elevated right 1st rib. Dynamic impairments included premature passive and active clavicular posterior rotation and diminished scapular upward rotation during upper extremity elevation. These impairments may have contributed to narrowed thoracic outlet spaces [1,13,14]. His prognosis was favorable given his positive Cyriax release test and nocturnal symptoms indicating a release phenomenon [10,15]. He had no clinical findings consistent with true neurogenic deficits further decreasing the likelihood of true axonal compression.

Treatment

Clinical management included 10 supervised sessions and home exercise over 8 weeks. Treatments involved manual therapy, positional unloading, neural

mobilizations, and upper quarter active control training.

Self-management

Nocturnal paresthesia was addressed with the Cyriax release maneuver. This self-management technique unloads the neurovascular bundle prior to bed [16]. This maneuver unloads the brachial plexus neural tension under the coracoid process and often results in the familiar paresthesia during the maneuver. It is recommended the posture is maintained as long as tolerated, up to 30 minutes, every evening until symptoms are no longer elicited during the maneuver [15]. He reported reduced paresthesia with less than 10 minutes of unloading initially.

Manual therapy & self mobility exercises

Joint specific grade IV glides were performed 2 minutes each, or until the end feel softened from hard to firm. Costovertebral high velocity inferior thrust targeted his elevated 1st rib position with the goal of unloading his costoclavicular and thoraco-coracopectoral spaces. Furthermore, joint traction high velocity thrusts and grade IV ventral glides were used to improve acromioclavicular and sternoclavicular mobility to allow more symmetrical clavicular elevation

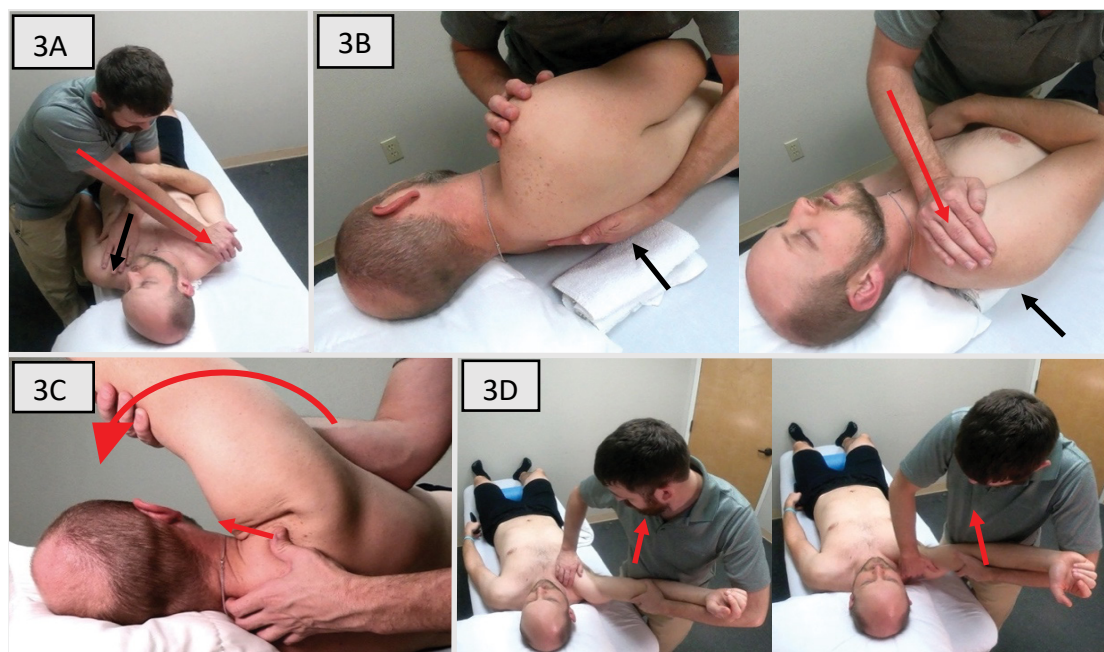


Figure 3: Joint specific mobilizations and neuromuscular re-education techniques performed 1-2 minutes each
KEY: Block. Arthrokinematics glide. Osteokinematic swing.

Sternoclavicular Joint (SCJ) Traction: Using a towel roll fulcrum between the scapula the contralateral scapula is stabilized on the mat. The distal clavicle is grasped, and axial distraction is provided.

Acromioclavicular Joint (ACJ) Traction: The blocking hand is supported at the medial scapula. The mobilizing hand grasps the coracoid, acromion, & proximal humerus avoiding the distal clavicle. Axial distraction is provided.

Acromioclavicular Curved Glide: The gliding thumb provides a ventral (relative to the moving scapula) glide of the distal clavicle towards the patients chin while an osteokinematic swing into elevation is provided.

Neuromuscular Re-education: The gliding hand nudges the clavicle in the arthrokinematic direction while larger osteokinematic arcs are induced passively, active assistive, and concentrically. Isometric elevation, depression, and elevation ends the technique.

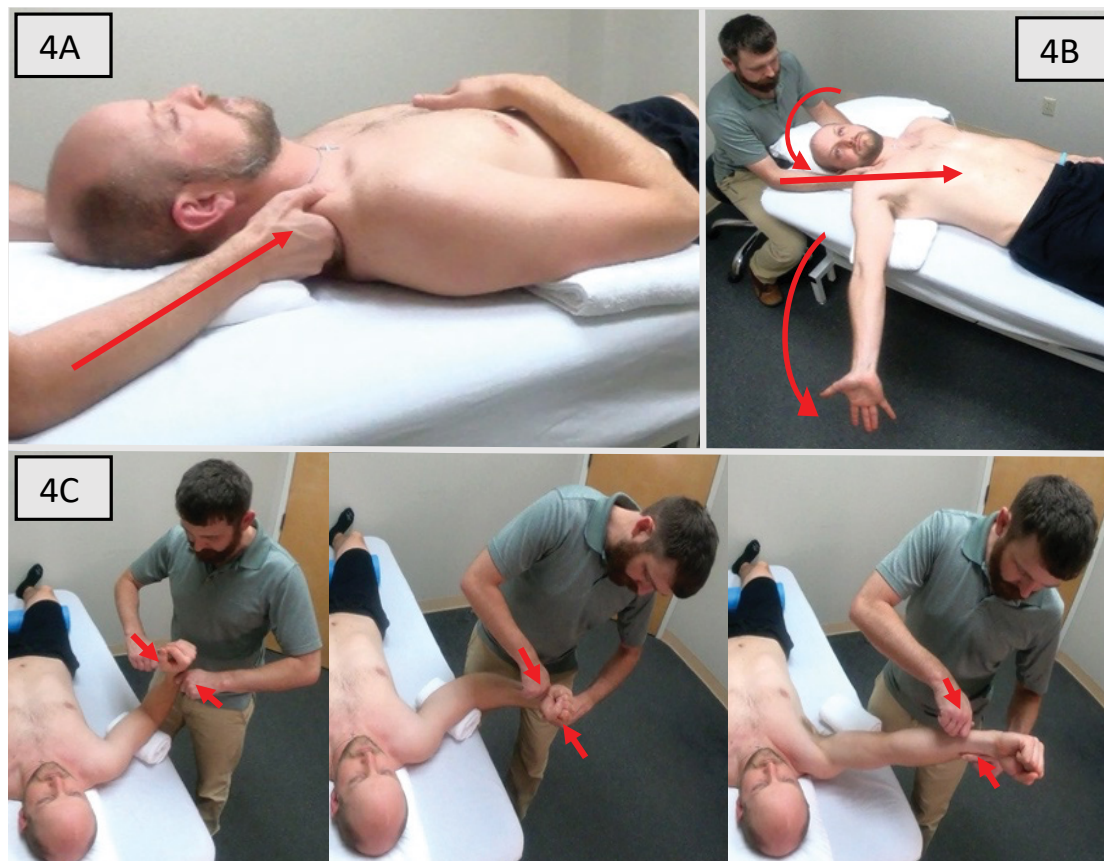


Figure 4: First rib glide, neural mobilizations, somatosensory training

First rib inferior glide: First rib is found inferiorly to the mastoid processes [26]. First rib inferior glide & high velocity thrust is assisted with patient exhalation.

Median nerve mobilization: Rhythmic neural mobilizations with sustained 1st rib inferior glide. This was performed 30-60 repetitions.

Rhythmic stabilizations: Alternating perturbations in various pre-positions are applied while the patient retains their position [27]. This was performed 1-2 minutes per position.

and posterior rotation during upper extremity elevation [15] (Figure 3). Self-mobility exercises complimenting the manual therapy, including 1st rib depression and thoracic mobility, were recommended.

Neural mobilizations

Prior to neural mobilization, the thoracic outlet impairments were treated with specific manual therapy to improve his right 1st rib expired position. The median ULNTT initially was provocative and elicited significant guarding when the elbow was near 30° flexion. Manual 1st rib inferior low amplitude high velocity thrust immediately improved full, pain free elbow extension with median ULNTT. Neural mobilization “sliders” facilitated the brachial plexus mobility through the thoracic outlet to mitigate tension and adhesive events [5,16] (Figure 4A and Figure 4B). Failure to perform manual therapy prior to neural mobilization would potentially result in increased tension to the irritable brachial plexus and result in symptom exasperation.

Active control training

He demonstrated diminished cervical deep neck flexor endurance and scapular upward rotation

during arm elevation. These dysfunctions may lessen proximal upper quarter control and contribute to dynamic shoulder girdle dysfunction [17-19]. Deep cervical endurance training and scapulothoracic muscle activation exercises was thus implemented [20,21]. Proper scapulothoracic behavior during arm elevation requires the appropriate balance between the lower trapezius, upper trapezius, and serratus anterior [19]. Reactivation of the lower trapezius and serratus anterior was achieved with the exercises purposed by Kibler, et al. [22] Scapulothoracic and rotator cuff strengthening was followed by perturbation training to promote dynamic shoulder stability during elevation [23]. Perturbation training encompassed shoulder rhythmic stabilizations to improve reflexive reactivation, neuromuscular control, and proprioception in various positions [24] (Figure 4C). These procedures were performed 1-3 minutes each after manual therapy.

Outcomes & Follow Up

Patient began to report diminished nocturnal paresthesia by the 3rd session resolving by the 6th. Moreover, he reported improved overhead reaching endurance, less hand pallor. By session 8 he stated

throwing a football was greater ease.

At his 10th session discharge Cyriax release and elevated arm stress test were non-provocative for a sustained 2 minutes. He displayed symmetrical, normalized symmetrical clavicular motion during passive elevation, 60° upward scapular rotation, and symmetrical cervical rotation lateral flexion test [25]. His median nerve ULNTT was unlimited and pain free. The deep neck flexor endurance improved from 20 to 89 seconds and his DASH scores reduced from 12.9 to 4.3 (Raw score 34/29 questions), which may or may not have exceeded the DASH MCID value.

One-year follow up revealed very minor hand paresthesia and no return of overhead pallor, fatigue. His DASH score was 1.7 (Raw Score: 31/29 questions). He was able to continue playing football the following season.

Discussion

To our knowledge most TOS literature includes review articles describing clinical diagnostics and proposed treatment approaches. However, to date the research regarding the conservative management effectiveness on adolescents nTOS secondary to shoulder girdle mobility impairments is negligible.

In this case specific treatments were based on impairments identified in the clinical examination. Specific findings beget specific manual therapy to reduce tissue irritability and improve mobility. However, this alone is insufficient to restore functional active control [26]. Thus, the treatment plan included cervical, scapulothoracic, rotator cuff activation progressed to overhead control. The patient experienced immediate reduction in symptoms by the 2nd session after performing the Cyriax release at home and undergoing 1st rib inferior manipulations. Further sessions focused on optimize control of his newly gained passive shoulder girdle mobility and monitor his return to sport.

Manual therapy improved his passive clavicular mobility with joint play tests and normalized clavicular behavior with passive elevation. Afterwards, during active elevation his scapular upward rotation was symmetrical with his left and symptom free. Active control training in the newly gained ranges followed the joint specific manual techniques. These improvements persisted through his 1-year follow up and he reported being able to participate in collegiate football and military training.

These case report limitations include no validating diagnostic studies to confirm nTOS, multiple concurrent treatments prevent any ability to determine if one contributed more heavily to these outcomes. Lastly, this is a single subject case report with no randomization. No clinical causation may be inferred. Future studies should include randomized trials with more subjects to

further our understanding regarding the effectiveness of conservative management in clinically suspected nTOS patients.

Conclusion

A cluster of positive thoracic outlet provocation tests coupled with a thorough upper quarter orthopedic and functional evaluations lead to specific manual and active control training. This provided the foundation for successful management of an adolescent quarterback with suspected disputed nTOS case.

Learning Points

In this case:

- A thorough clinical examination was paramount to identify contributing impairments leading to a specific plan of care.
- First rib inferior manipulation improved the 1st rib expiration positioning allowing for brachial plexus neural mobilization.
- Manual acromioclavicular and sternoclavicular techniques addressed mobility deficits before active upper quarter control training.

Financial Disclosure and Conflict of Interest

I affirm that I have no financial affiliation (including research funding) or involvement with any commercial organization that has a direct financial interest in any matter included in this manuscript, except as disclosed and cited in the manuscript. Any other conflict of interest (i.e, personal associations or involvement as a director, officer, or expert witness) is also disclosed and cited in the manuscript.

References

1. Remy-Jardin M, Doyen J, Remy J, Artaud D, Fribourg M, et al. (1997) Functional anatomy of the thoracic outlet: evaluation with spiral CT. *Radiology* 205: 843-851.
2. Hooper TL, Denton J, McGilliard MK, Brismée JM, Sizer PS (2010) Thoracic outlet syndrome: a controversial clinical condition. Part 1: Anatomy, and clinical examination/diagnosis. *J Man Manip Ther* 18: 74-83.
3. Hixson KM, Horris HB, McLeod TCV, Bacon CEW (2017) The Diagnostic accuracy of clinical diagnostic tests for thoracic outlet syndrome. *J Sport Rehabil* 26: 459-465.
4. Gillard J, Pérez-Cousin M, Hachulla É, Remy J, Hurtevent JF, et al. (2001) Diagnosing thoracic outlet syndrome: contribution of provocative tests, ultrasonography, electrophysiology, and helical computed tomography in 48 patients. *Joint Bone Spine* 68: 416-424.
5. Brismée JM, Phelps V, Sizer P (2005) Differential diagnosis and treatment of chronic neck and upper trapezius pain and upper extremity paresthesia: A case study involving the management of an elevated first rib and uncovertebral joint dysfunction. *J Man Manip Ther* 13: 79-90.
6. Zuckerman SL, Kerr ZY, Pierpoint L, Kirby P, Than KD, et al. (2019) An 11-year analysis of peripheral nerve injuries in high school sports. *Phys Sportsmed* 47: 167-173.

7. Pearson MR (1994) Posterior sternoclavicular dislocation: A case report. *J Emerg Med* 12: 783-787.
8. Hartley RA, Kordecki ME (2018) Rehabilitation of chronic brachial plexus neuropraxia and loss of cervical extension in a high school football player: A case report. *Int J Sports Phys Ther* 13: 1061-1072.
9. Dabija DI, Jain NB (2019) Minimal clinically important difference of shoulder outcome measures and diagnoses: A systematic review. *Am J Phys Med Rehabil* 98: 671-676.
10. Domenech MA, Sizer PS, Dedrick GS, McGalliard MK, Brismée JM (2011) The deep neck flexor endurance test: Normative data scores in healthy adults. *PMR* 3: 105-110.
11. Sanders RJ, Hammond SL, Rao NM (2007) Diagnosis of thoracic outlet syndrome. *J Vasc Surg* 46: 601-604.
12. Brismée JM, Gilbert K, Isom K, Hall R, Leathers B, et al. (2004) Rate of false positive using the cyriax release test for thoracic outlet syndrome in an asymptomatic population. *J Man Manip Ther* 12: 73-81.
13. Fung M, Kato S, Barrance PJ, Elias JJ, McFarland EG, et al. (2001) Scapular and clavicular kinematics during humeral elevation: A study with cadavers. *J Shoulder Elbow Surg* 10: 278-285.
14. Richardson AB (1999) Thoracic outlet syndrome in aquatic athletes. *Clin Sports Med* 18: 361-378.
15. Winkel D, Matthijs O, Phelps V (1997) Diagnosis and treatment of the upper extremities: Nonoperative medicine and manual therapy. Aspen Publishers.
16. Hooper TL, Denton J, McGalliard MK, Brismée JM, Sizer Jr PS (2010) Thoracic outlet syndrome: a controversial clinical condition. Part 2: Non-surgical and surgical management. *J Man Manip Ther* 18: 132-138.
17. Falla D, Jull G, Hodges PW (2004) Feed forward activity of the cervical flexor muscles during voluntary arm movements is delayed in chronic neck pain. *Exp Brain Res* 157: 43-48.
18. McGill S (2017) Ultimate back fitness and performance. (6th edn), Wabuno Publishers.
19. Novak C (2003) Thoracic outlet syndrome. *Clin Plast Surg* 30: 175-188.
20. Jull G, Falla D, Treleaven J, Hodges P, Vicenzino B (2007) Retraining cervical joint position sense: The effect of two exercise regimes. *J Orthop Res* 25: 404-412.
21. Falla D, Jull G, Hodges P, Vicenzino B (2006) An endurance-strength training regime is effective in reducing myoelectric manifestations of cervical flexor muscle fatigue in females with chronic neck pain. *Clin Neurophysiol* 117: 828-837.
22. Kibler WB, Sciascia AD, Uhl TL, Tambay N, Cunningham T (2008) Electromyographic Analysis of Specific Exercises scapular control in early phases of shoulder rehabilitation. *Am J Sports Med* 36: 1789-1798.
23. Reinold MM, Escamilla R, Wilk KE (2009) Current concepts in the scientific and clinical rationale behind exercises for glenohumeral and scapulothoracic musculature. *J Orthop Sports Phys Ther* 39: 105-117.
24. Wilk KE, Macrina LC (2013) Nonoperative and postoperative rehabilitation for glenohumeral instability. *Clin Sports Med* 32: 865-914.
25. Lindgren KA, Leino E, Manninen H (1992) Cervical rotation lateral flexion test in brachialgia. *Arch Phys Med Rehabil* 73: 735-737.
26. Moreside JM, McGill SM (2013) Improvements in hip flexibility do not transfer to mobility in functional movement patterns. *J Strength Cond Res* 27: 2635-2643.