



CASE REPORT

Non-Traumatic First Rib Fracture in University Wrestler

Thomas Wesley Allen, DO, MPH, FACP, FAOASM*

Oklahoma State University, USA

*Corresponding author: Thomas Wesley Allen, DO, MPH, FACP, FAOASM, Oklahoma State University, Oklahoma State Wrestling, 460 Athletics Center, Stillwater, OK 74078, USA



Abstract

The first rib is well situated to be fully protected from external trauma as it is surrounded by soft tissue, muscles, and bony structures. It is rarely fractured by external trauma. However, two reports of non-traumatic first rib fractures have recently been reported: One in a basketball player and the other in a cheerleader. We present a third case of a non-traumatic first rib fracture, one that occurred in a collegiate wrestler secondary to cervical muscle contraction.

Keywords

First rib, First rib stress fracture, Sports injuries, Wrestling

Introduction

The first rib is the shortest of the 12 bilateral ribs and attaches to the first vertebral body posteriorly and to the manubrium anteriorly.

The first rib is well situated to be fully protected by external trauma as it is surrounded by soft tissue, muscles, and bony structures. However, a report of two non-traumatic first rib fractures has recently been published [1]. We present a third case of a non-traumatic first rib fracture secondary to scalene muscle contraction in a university wrestler. No previous reports of non-traumatic first rib fractures in wrestlers have been published.

Found on the first rib are several structures which are vulnerable to damage should a fracture occur. The subclavian vein and subclavian artery cross the first rib in grooves on the superior surface and may be torn by forceful scalene muscle contraction at its attachment at the scalene tubercle between the vascular grooves (Figure 1).

Case Report

A 19-year-old varsity wrestler presented with a history of being thrown from his feet by another wrestler in the practice room. He suddenly developed pain in the right medial parascapular area. He recalls that as he was thrown on his left shoulder, he flexed his head to the right to avoid striking his head on the mat.

He continued to wrestle with some tolerable back and shoulder pain but after practice he had increased stiffness and soreness in his right upper back. He complained of pain on movement of the right shoulder. Tenderness to palpation of the right rhomboid muscle was elicited but no tenderness over the scapula or spinous processes. Neurological exam was normal. He denied numbness, weakness or weakness in his right arm. The initial impression was possible right rhomboid strain.

A follow-up examination 48 hours after the injury revealed no significant change in signs or symptoms. However, a chest X-ray revealed a non-displaced fracture of right first rib. A thoracic MRI revealed normal rhomboid, but a small right pleural effusion was visualized. A CT of the thorax revealed a non-displaced first rib fracture (Figure 2).

Follow-Up

The wrestler was permitted to engage in aerobic exercise only with no wrestling and no weight lifting for 6 weeks. He was then allowed to resume wrestling and weight lifting without limitation. No untoward after-effects were experienced.

Discussion

Because of its location, the first rib is seldom frac-

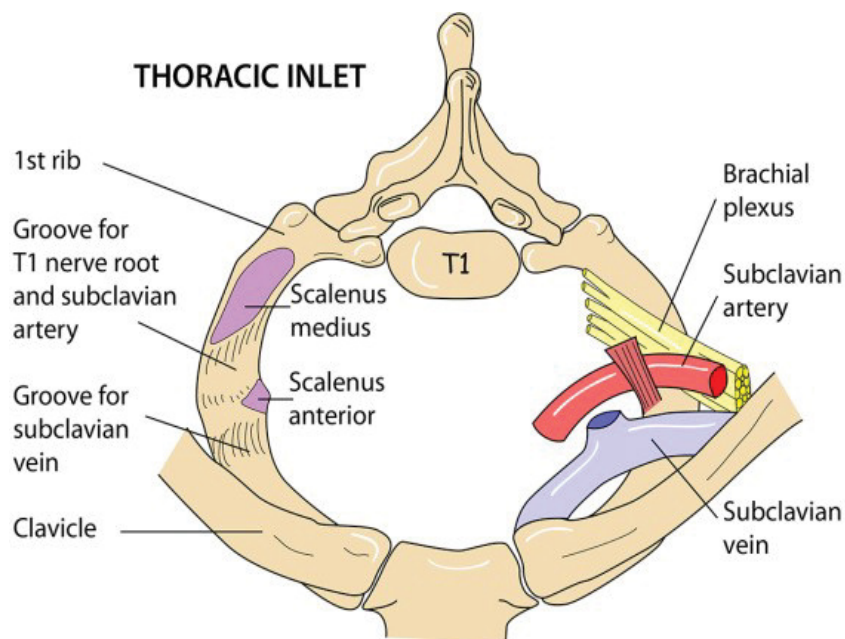


Figure 1: Thoracic Inlet at the level of First Rib.

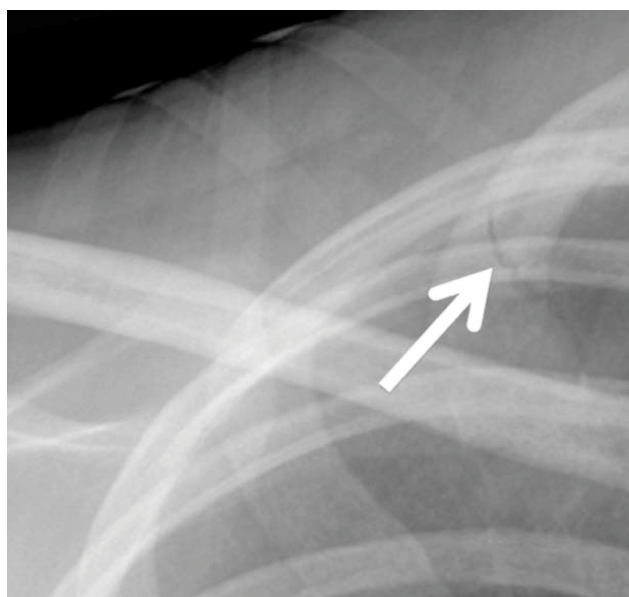


Figure 2: CT Scan of Right Upper Thorax with Arrow at Fracture of First Rib.

tured without severe external trauma [2]. However, several reports of first rib fractures without severe trauma have been published [2-5].

The unique anatomy of the first rib lends itself to fracture in the event of sudden neck muscle contraction without external trauma [1]. Non-traumatic fractures of the first rib have been reported athletes participating in several sports including football [3], baseball [4], soc-

cer [5], basketball [6], kick boxing [7] and rugby [8]. This case is the first reported in a wrestler at any level.

Funding Statement

The author received no funding for this report.

References

1. Weis JL (2019) Non-Traumatic First Rib Fractures Secondary to Opposing Muscle Contractions: A Case Series. *International Journal of Sports and Exercise Medicine* 5: 1-4.
2. Richardson JD, McElvein RB, Trinkle JK (1975) First rib fracture: a hallmark of severe trauma. *Ann Surg* 181: 251-254.
3. Barrett GR, Shelton WR, Miles JW (1988) First rib fractures in football players. *Am J Sports Med* 16: 674-676.
4. Chimenti PC, Elfar JC, Giordano BD (2013) Dominant-Sided First-Rib Stress Fracture in a Collegiate Baseball Pitcher: A Case Report. *JBJs Case Connect* 3: e1081-e1084.
5. Matsumoto T, Fujita K, Fujioka H, Tsunoda M, Yoshiya S, et al. (2003) Stress fracture of the first rib in a soccer player: a rare etiology of shoulder pain. *J Shoulder Elbow Surg* 12: 197-199.
6. Sachetti AD, Beswick DR, Morse SD (1983) Rebound rib: Stress-induced first rib fracture. *Ann Emerg Med* 12: 177-179.
7. Sakellaris T, Stamatelopoulos A, Andrianopoulos E, Kormas P (2004) Isolated first rib fractures in athletes. *Br J Sports Med* 38: 5.
8. Vkramaditya, Pritty P (2001) Two cases of isolated first rib fracture. *Emerg Med J* 18: 498-499.