



## CASE REPORT

# Craniofacial Fibrous Dysplasia: Is Alkaline Phosphatase an Accurate Marker of Disease Activity?

Wyatt Nice<sup>1\*</sup>, Kezia Daniel<sup>1</sup>, Kathleen Brindle<sup>2</sup> and Rodolfo Curiel<sup>1</sup>

<sup>1</sup>Division of Rheumatology, Department of Medicine, The George Washington University School of Medicine and Health Sciences, USA

<sup>2</sup>Department of Radiology, The George Washington University School of Medicine and Health Sciences, USA

\*Corresponding author: Wyatt Nice, Division of Rheumatology, Department of Medicine, The George Washington University School of Medicine and Health Sciences, USA, Tel: 207-776-3832



## Abstract

Fibrous dysplasia is a rare benign bone condition in which mature bone is replaced with fibrous tissues. Disease activity is most prominent in the first three decades of life before becoming inactive. Elevations in alkaline phosphatase have been known to be present during times of active disease, however, the clinical utility of using alkaline phosphatase to monitor disease progression remains unclear. We present the case of a 72-year-old woman with a history of craniofacial fibrous dysplasia clinically inactive since childhood who presented with asymptomatic elevations of alkaline phosphatase for 4 years duration. Workup suggested her previously diagnosed fibrous dysplasia as the cause of her elevated alkaline phosphatase despite lack of disease activity for decades, thus showing that alkaline phosphatase is not an accurate marker of disease activity. These findings underscore the need for further research into the pathophysiology and clinical relevance of elevated alkaline phosphatase in fibrous dysplasia.

## Keywords

Fibrous dysplasia, Alkaline phosphatase

## Abbreviations

ALP: Alkaline Phosphatase

## Introduction

Fibrous dysplasia is a rare disorder of bone development in which mature bone is replaced by immature fibrous tissue. The etiology is a postzygotic mutation in the GNAS gene affecting development of normal bone stromal cells, leading to their replacement

with fibrous tissue and immature woven bone [1]. It can be monostotic or polyostotic, and can occur in isolation or as part of McCune-Albright syndrome, which consists of the triad of polyostotic fibrous dysplasia, cafe-au-lait spots, and endocrine abnormalities. Fibrous dysplasia is commonly diagnosed in the first three decades of life and most frequently affects the femur. Involvement of the craniofacial bones occurs in a minority of cases and can cause compression of cranial nerves. Diagnosis can often be made with characteristic radiographic findings, which demonstrate a ground glass appearance that is distinct from other bone malignancies [2]. Histologic analysis can be used when the diagnosis is uncertain. Treatment is limited generally to monitoring and surgical correction of associated fractures and deformities. Bisphosphonates have been shown to improve pain and risk of fractures [3]. Monostotic fibrous dysplasia tends to become inactive after puberty, while polyostotic may remain active throughout life. The risk of malignant transformation is low (0.4-4.0%), and is notably higher in McCune-Albright syndrome [4].

Alkaline phosphatase is a key enzyme used during bone development and turnover. Elevated serum levels of the bone specific isoform are commonly associated with active bone diseases, such as Paget's disease and bony metastasis. In this report, however, we explore the seemingly perplexing relationship between persistently elevated levels of alkaline phosphatase despite clinically and radiographically stable fibrous dysplasia.



**Citation:** Nice W, Daniel K, Brindle K, Curiel R (2024) Craniofacial Fibrous Dysplasia: Is Alkaline Phosphatase an Accurate Marker of Disease Activity?. Int J Rare Dis Disord 7:058. doi.org/10.23937/2643-4571/1710058

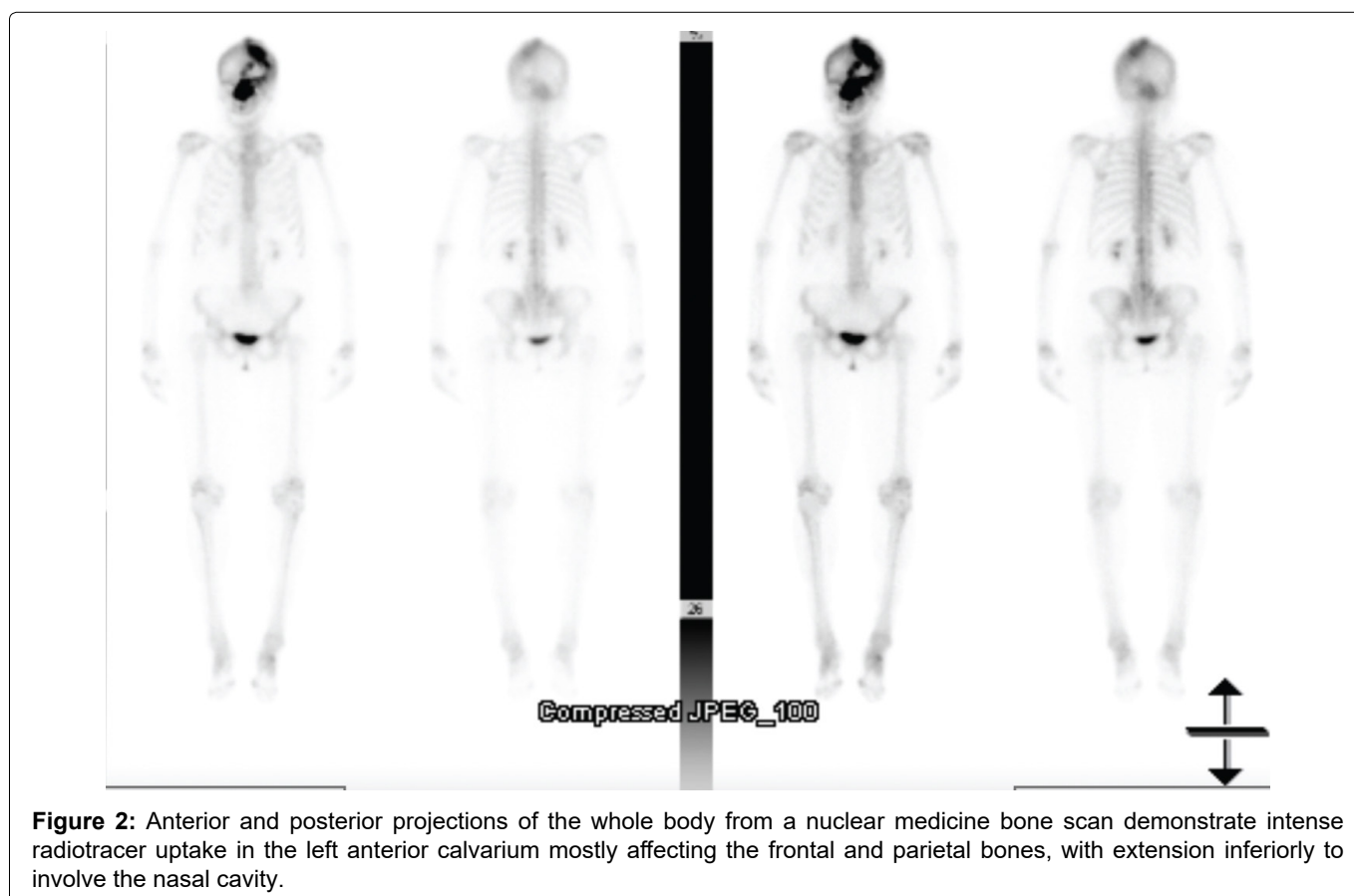
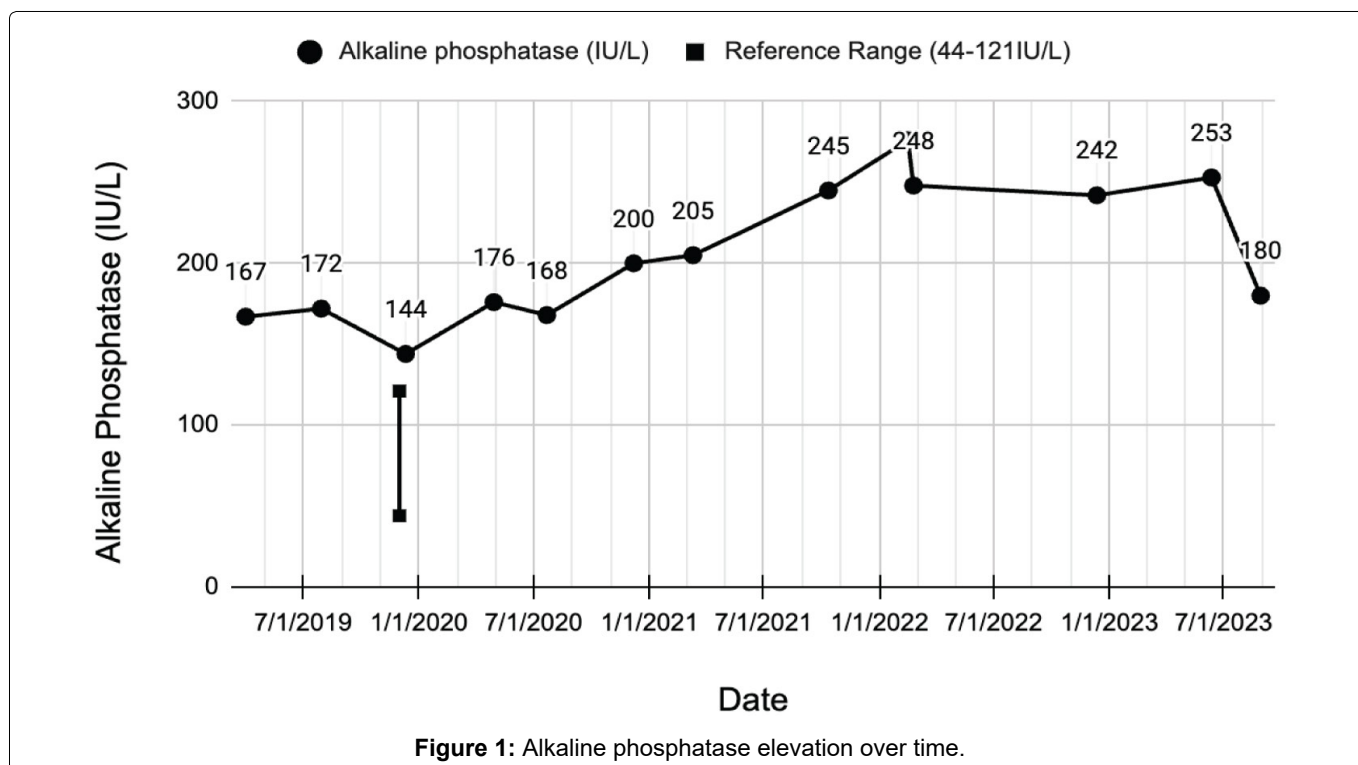
**Accepted:** February 08, 2024; **Published:** February 10, 2024

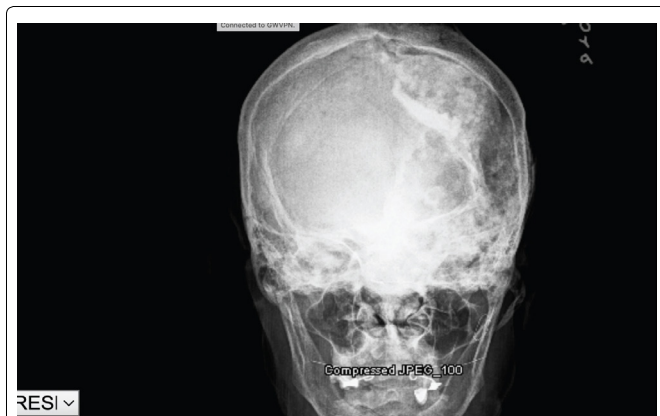
**Copyright:** © 2024 Nice W, et al. This is an open-access article distributed under the terms of the Creative Commons Attribution License, which permits unrestricted use, distribution, and reproduction in any medium, provided the original author and source are credited.

## Case Presentation

A 72-year-old female with a history of craniofacial fibrous dysplasia with optic nerve compression and left eye blindness since childhood presented with asymptomatic elevation in Alkaline phosphatase (ALP). Prior records show persistent elevation of ALP for at least 4 years with a nadir of 144 IU/L and a maximum of 276 IU/L (normal 44-121 IU/L) (Figure 1). Abdominal

ultrasound showed gallbladder sludge but otherwise normal liver and bile ducts. The bone specific ALP isoform was elevated at 76% (normal 14-68%). AST, ALT and bilirubin were within normal limits. Whole body bone scan showed intense radiotracer uptake in the left anterior calvarium mostly affecting the frontal and parietal bones, with extension inferiorly to involve the nasal cavity (Figure 2). This was unchanged from





**Figure 3:** Frontal view of the skull demonstrates deformity of multiple bones in the left calvarium with mixed lucency and patchy sclerosis. There is widening of the diploic space and focal bulging of the outer table along the midline superiorly.

a previous bone scan 17 years prior, without signs of increased bone turnover elsewhere in the body. X-ray of the skull showed a large area of ill-defined heterogeneous bone, consisting of sclerotic and lucent bone changes involving the left frontal and parietal regions consistent with fibrous dysplasia (Figure 3). There was no evidence of any malignant transformation. These radiographic and scintigraphic findings, with an otherwise negative bone scan, established the diagnosis of fibrous dysplasia as the most likely cause of her elevated ALP. Her symptoms had been clinically stable for decades despite the persistent elevation in ALP.

## Discussion

Fibrous dysplasia is a rare disorder of bone development in which mature bone is replaced by immature fibrous tissue. Often diagnosed in childhood and inactive by adulthood, it is a condition infrequently treated by physicians who care for older populations. Some studies correlate elevated ALP levels with disease progression, and suggest that ALP can be used to monitor disease progression [5-7]. Other studies have found that ALP levels may remain elevated despite inactive disease [8]. Some of these same studies have also demonstrated that only a minority of patients with active or recurrent disease after surgical treatment have elevated ALP levels to begin with [5]. Hence, the utility of using ALP as a marker for disease activity or as a sign of malignant transformation remains unclear. We

present a case where ALP remained elevated for many years despite stable disease without any malignant transformation.

ALP thus appears not to be a reliable marker of malignant transformation or clinically significant disease activity. Nonetheless, ALP elevation should always be worked up in the setting of fibrous dysplasia because malignant transformation and active disease in adulthood are possible. Clinicians ought to be aware that patients with remote histories of fibrous dysplasia may present many years later with continued elevations in ALP. As illustrated in this case, imaging studies, particularly radionuclide bone scans, can be instrumental in determining whether ALP elevations are due to previously diagnosed fibrous dysplasia or a newly emergent pathology. They can also assess for disease progression. More research into the pathophysiology of ALP in fibrous dysplasia is needed to understand why the profile varies between patients seemingly irrespective of disease status.

## References

1. Lee J, FitzGibbon E, Chen YR, Kim HJ, Lustig LR, et al. (2012) Clinical guidelines for the management of craniofacial fibrous dysplasia. *Orphanet J Rare Dis* 7: S2
2. Fitzpatrick KA, Taljanovic MS, Speer DP, Graham AR, Jacobson JA, et al. (2004) Imaging findings of fibrous dysplasia with histopathologic and intraoperative correlation. *AJR Am J Roentgenol* 182: 1389-1398.
3. Lane JM, Khan SN, Connor WJO, Nydick M, Hommen J P, et al. (2001) Bisphosphonate therapy in fibrous dysplasia. *Clin Orthop Relat Res* 382: 6-12.
4. Lee CJ, Kim SM (2005) Malignant transformation of fibrous dysplasia on anterior skull base. *J Korean Neurosurg Soc* 37: 383-385.
5. Onyebuchi EP, Ajike SO, Yusuf R, Fomete B (2022) Alkaline phosphatase profile of patients with fibro-osseous lesions. *Iran J Otorhinolaryngol* 34: 311-318.
6. Wang J, Du Z, Li D, Yang R, Tang X, et al. (2020) Increasing serum alkaline phosphatase is associated with bone deformity progression for patients with polyostotic fibrous dysplasia. *J Orthop Surg Res* 15: 583.
7. Senn D, Mirzazadeh M (2020) A rare case of raised alkaline phosphatase - polyostotic fibrous dysplasia. *Int J Rare Dis Disord* 3: 021.
8. Ma J, Liang L, Gu B, Zhang H, Wen W, et al. (2013) A retrospective study on craniofacial fibrous dysplasia: preoperative serum alkaline phosphatase as a prognostic marker? *J Craniomaxillofac Surg* 41: 644-647.