



## CASE REPORT

# Anesthetic Management of the Case of Removal of Tracheobronchial Foreign Body in a Whistling Child: A Case Report

Renu Sinha, MD<sup>1</sup>, Ruma Thakuria, MD<sup>2</sup>, Hitesh Verma, MD<sup>3</sup> and Abhishek Singh, MD<sup>4\*</sup>



<sup>1</sup>Professor, Department of Anesthesiology, Pain Medicine and Critical Care, All India Institute of Medical Sciences, New Delhi, India

<sup>2</sup>Assistant Professor, Department of Anesthesiology, All India Institute of Medical Sciences, Rishikesh, India

<sup>3</sup>Additional Professor, Department of Ear, Nose and Throat, All India Institute of Medical Sciences, New Delhi, India

<sup>4</sup>Assistant Professor, Department of Anesthesiology, Pain Medicine and Critical Care, All India Institute of Medical Sciences, New Delhi, India

\*Corresponding author: Abhishek Singh, MD, Assistant Professor, Department of Anesthesiology, Pain Medicine and Critical Care, All India Institute of Medical Sciences, Room no 322A, JPNATC, AIIMS, New Delhi, 110029, India, Tel: +918287652624

## Abstract

Tracheobronchial foreign body pose an anesthetic challenge due to their propensity to cause partial or complete airway obstruction resulting in a need for urgent bronchoscopy and removal. Diagnosis mainly depends on taking proper history and radiological investigation which should demonstrate the time, type and location of the foreign body. The most suitable type of anesthesia and ventilation should be chosen that reduces the risk of complications, morbidity and mortality. Here, we describe the case of 13-year-old boy who had aspirated a whistle while playing. The clinical signs, diagnosis and anesthetic management of a tracheobronchial foreign body are discussed.

## Keywords

Anesthesia, Foreign body, Tracheobronchial tree

## Glossary

FB: Foreign Body

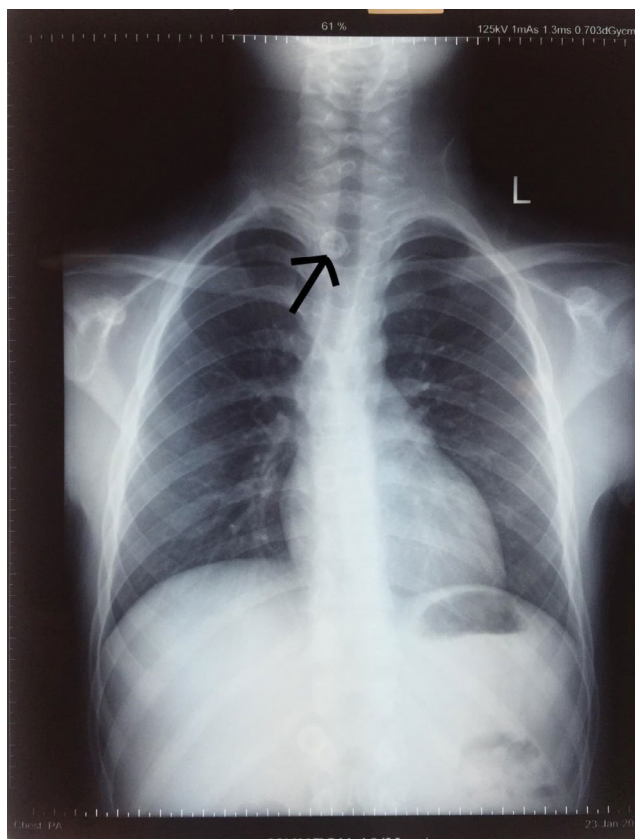
awareness and highest degree of suspicion regarding clinical manifestation of foreign body aspiration in the airway [3]. Certain factors like low airway protective reflex, exploring nature, eating while crying or playing, poor chewing capability and lack of molars renders children prone to aspiration of the foreign body [4]. Early diagnosis and removal of foreign body is associated with significant reduction in complications and mortality. Certain concerns which need special attention while managing such cases are maintenance of a patient airway, prevention of airway obstruction, maintenance of stable level of anesthesia, prevention of hypoxemia due to shared airway and possible post-operative complications. Here, we describe the anesthetic management for the removal of the foreign body from the bronchus of a 13-year-old boy who had aspirated a whistle while playing. His father has given informed written consent for publishing the image related to the case.

## Introduction

Aspiration of the foreign body is the most common surgical emergency in the pediatric patients with significant risk of morbidity and mortality [1,2]. The effective management of this condition requires

## Case Description

A 13-year-old male child presented to the emergency department with a 3-day history of aspiration of foreign body. The child had no other co-morbidities



**Figure 1:** Chest X-ray showing location of foreign body.



**Figure 2:** Foreign body.

or symptoms of upper respiratory tract infection. The physical examination was within normal limit except for whistling sound during each inspiration (Video 1). The parents reported that he had accidentally inhaled the foreign body while playing. Radiography of the chest revealed the presence of round shaped foreign body in the trachea probably in the subglottic area of larynx (Figure 1). Anesthesia was induced with sevoflurane in oxygen while maintaining spontaneous respiration. After achieving adequate depth of anesthesia, rigid bronchoscope was placed and non-depolarizing muscle relaxant (atracurium) was given to prevent patient movement, reflex and airway trauma. Stable depth of anesthesia was maintained during the procedure by using infusion of propofol. A rigid bronchoscopy was done and a whistle (Figure 2) was retrieved from right main bronchus. The procedure was uneventful and the child is doing well at 3 years follow up.

## Discussion

Anesthetic management for removal of tracheobronchial foreign body (FB) in pediatric population is challenging since it is extremely difficult to maintain the airway for oxygenation and ventilation in the patients whose lung function has already been compromised due to presence of foreign body. Different foreign body has varied clinical presentation. Subglottic FB mainly presents with cough which may resolve after sometime due to fatigue and adaptation [5]. Stridor and dysphonia are the common symptoms

of a laryngotracheal FB. Plastic FB are often diagnosed late due to their translucency and delayed onset of obstructive symptoms [6]. In this patient, the only symptom was whistling sound during inspiration. It did not cause any respiratory distress since the hollow structure of the whistle allowed inspiration and expiration through the lumen.

Effective anesthetic management need proper preanesthetic assessment of all the cases. Bilateral air entry should be checked and chest X-ray should be examined to determine the location of the FB, degree of airway obstruction and to rule out pneumonia, atelectasis and air trapping. History regarding comorbidities, room air oxygen saturation and informed written consent should be taken from parents/guardian during preoperative visit.

It is important to maintain the spontaneous ventilation during induction of anesthesia as loss of spontaneous ventilation may prove catastrophic in case of total airway obstruction by the foreign body. Muscle relaxants may be used during the procedure when it has been confirmed that the ventilation through the side port is possible either with the FB *in situ* or it has been pushed distally into the right bronchus. Controlled ventilation has the advantage of better oxygenation, and ventilation, reduced anesthetic requirements, reduced coughing, movement, bucking and airway trauma during the procedure [7].

Maintenance of anesthesia can be done by using

inhalational agents. Sevoflurane is preferred for fast induction, recovery and being least irritant to the airway. But there is risk of operation room pollution due to escape of gas from the bronchoscope necessitating high flows requirement to maintain the depth of anesthesia. Constant level of anesthesia can also be achieved with propofol-remifentanyl infusion. Anesthesia can be maintained with either inhalation or intravenous based approach since there is no evidence of superiority of one method over the other [8].

Type of anesthetic used and ventilation method (controlled or spontaneous) should ensure that there is least risk of complication and mortality [9]. In this patient, anesthesia was induced with sevoflurane in oxygen while maintaining spontaneous respiration. After achieving adequate depth of anesthesia, rigid bronchoscope was placed and non-depolarizing muscle relaxant (atracurium) was given to prevent patient movement, reflex and airway trauma. Stable depth of anesthesia was maintained during the procedure by using infusion of propofol.

After the procedure, all patients should be kept under observation in the recovery area for diagnosing any signs of respiratory distress, stridor or bronchospasm. A chest X-ray should be done to exclude the presence of pneumothorax or mediastinal emphysema due to barotraumas.

## Conclusion

The most common surgical emergency in pediatric patients is a tracheobronchial foreign body. Proper parental education and awareness can prevent such complications. Suspicious history and symptoms should prompt evaluation by bronchoscopy in order to reduce complications and mortality. It should be done after proper planning and after a detailed clinical and radiological investigation. Different anesthesia techniques can be used for managing such children, but there is no evidence of the superiority of one method over the other. Regardless of the management strategy, close cooperation between the surgical and anesthesia teams is necessary to avoid the complications associated with foreign body aspiration.

## Conflict of Interest

None.

## Financial Disclosure

None.

## Author Contribution

Renu Sinha: This author contributed to patient management and literature review, and drafted and edited the article; Abhishek Singh: This author has prepared the draft of the manuscript; Hitesh Verma: This author has contributed to patient management and revised the manuscript.

## References

1. Kendigelen P (2016) The anaesthetic consideration of tracheobronchial foreign body aspiration in children. *J Thorac Dis* 8: 3803-3807.
2. Bould MD (2019) Essential notes: The anaesthetic management of an inhaled foreign body in a child. *BJA Educ* 19: 66-67.
3. Kalyanappagol VT, Kulkarni NH, Bidri LH (2007) Management of tracheobronchial foreign body aspirations in paediatric age group-A 10 year retrospective analysis. *Indian Journal of Anaesthesia* 51: 20-23.
4. Patel JB, Chauhan A (2019) Anesthetic Management of Tracheobronchial Foreign Body Aspiration Cases in Children. *Acad. Anesthesiol Int* 4: 214-217.
5. Kaur K, Sonkhya N, Bapna AS (2002) Foreign bodies in the tracheobronchial tree: A prospective study of fifty cases. *Indian J Otolaryngol Head Neck Surg* 54: 30-34.
6. Bloom DC, Christenson TE, Manning SC, Eksteen EC, Perkins JA, et al. (2005) Plastic laryngeal foreign bodies in children: a diagnostic challenge. *Int J Pediatr Otorhinolaryngol* 69: 657-662.
7. Litman RS, Ponnuri J, Trogan I (2000) Anesthesia for tracheal or bronchial foreign body removal in children: An analysis of ninety-four cases. *Anesth Analg* 91: 1389-1391.
8. Farrell PT (2004) Rigid bronchoscopy for foreign body removal: Anaesthesia and ventilation. *Paediatr Anaesth* 14: 84-89.
9. Tomaske M, Gerber AC, Weiss M (2006) Anesthesia and periinterventional morbidity of rigid bronchoscopy for tracheobronchial foreign body diagnosis and removal. *Paediatr Anaesth* 16: 123-129.