



Penile Subcutaneous Stone Implant: An Unusual Case Report

Serdar Toksoz^{1*} and Yalcin Kizilkan²

¹Department of Urology, Samandag State Hospital, Hatay, Turkey

²Department of Urology, Baskent University School of Medicine, Ankara, Turkey

*Corresponding author: Serdar Toksoz, MD, Department of Urology, Samandag State Hospital, Hatay, Turkey, Tel: +90 312 2122912, Fax: +90 312 2154283, E-mail: serdartoksoz@gmail.com

Abstract

Introduction: Men in some areas of Asia have a long history of inserting or implanting various objects in their penises. Artificial penile implant are inert objects inserted beneath the skin of the penis.

Presentation of Case: We reported a case of 69-year-old man with penile subcutaneous stone implant for augmentation of penis.

Discussion: The penile bead implantation is performed largely due to the belief that it will enhance sexual performance and pleasure of female or male sexual partners during intercourse.

Conclusion: Studies among different groups suggests that penile implants were used to increase sexual confidence, as self ornamentation, to reinforce masculinity and as a marker for attaining manhood.

Keywords

Penis, Subcutaneous implantation, Penile stone

(Figure 1). There were no signs of inflammation it was learned that these nodules were actually objects with a stony structure, which had been implanted subcutaneously around the penile corpus by a circumcisional incision under local anesthesia thirty years ago in Saudi Arabia by a person without any medical training, for the purpose of penis augmentation. It was also learned that he was satisfied with his partner and he was having no problem during coitus. However, his partner was complaining about pain during coitus in recent years, which was associated with vaginal dryness. He wanted these stony objects to be removed from his penis, while having ureteral stone operation. Socio-cultural and religious reasons had affected the patient's penile subcutaneous object removal decision. After the ureteral stone operation, we incised the skin and excised all of the stony objects (Figure 2 and Figure 3). After the excision skin was sutured 4.0 vicryl primary.

Introduction

Men in some areas of Asia have a long history of inserting or implanting various objects into their penises. Artificial penile implant are inert objects inserted beneath the skin of the penis. Objects placed under the skin of the penile shaft may include plastic beads made from toothbrushes, silicon, metal pellets, glass, ivory, precious metals, marbles or pearls. Some men believe that penile implants enhance the sexual pleasure [1]. Subdermal implants placed under the skin of the penis can provide physical stimulation for both sexual partners. The most frequent form is genital beading, using small, round implants. The use of foreign bodies to enhance sexual experience is a practice that has been around for centuries. We reported a case of penile subcutaneous stone implant for augmentation of penis.

Case Report

A 69-year-old circumcised male patient, previously diagnosed with ureteral stone, was referred to our urology clinic for ureteral stone removal. During his physical examination three stony hard, mobile, smooth nodules, located at the dorsum of the penis were noticed. These nodules were approximately 1 cm in dimension, located within the coronal sulcus, at 11, 12, 1 o'clock positions

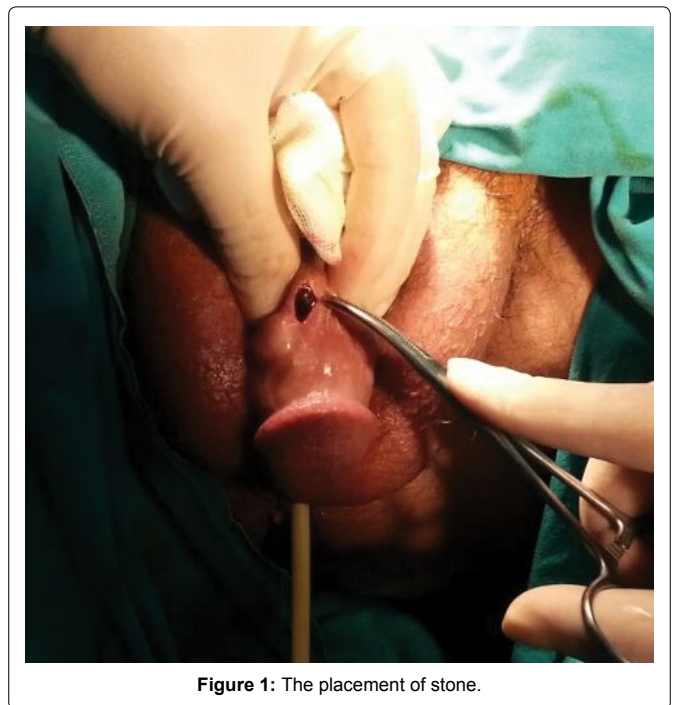

Figure 1: The placement of stone.

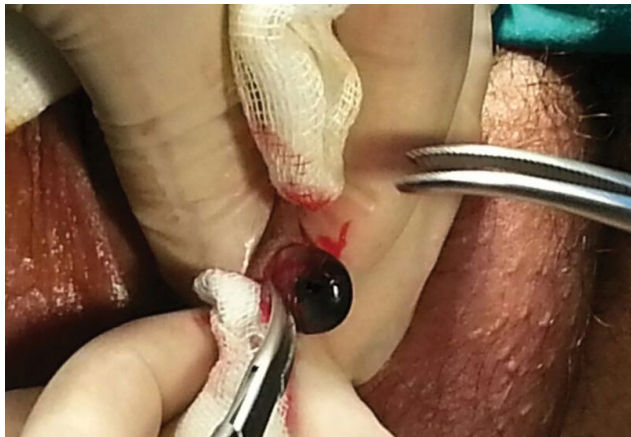

Figure 2: Extraction of stone.




Figure 3: Appearance of the stony object.

Discussion

There are various techniques for augmentation of penis. Some of these techniques may result without any inflammation or complication but some of them may lead to severe early and late complications. Al-Ansari et al. reported eight cases of subcutaneous cod liver oil injection for penile augmentation. All of these patients underwent emergency initial surgical intervention ranging from dorsal preputial slit to skin debridement [2]. Liquid injectable silicone has been used for soft tissue augmentation for over 50 years. Liquid injectable silicone may cause complications such as stony hard lobulated suprapubic mass, silicone migration, granulomatous mass, multiple firm nodular 1.5 cm masses circumferentially around the entire shaft, diffusely enlarged penis, firm penile edema [3-7]. Gurdal et al. reported penile subcutaneous stone implantation. This case is similar to ours; no complications had occurred in that case as well [8].

Conclusion

The cosmetic result of this implantation was not acceptable. However, no signs of inflammation or any late complication could be detected. Although this technique cannot be considered as an appropriate procedure in terms of contemporary surgery; this case aroused our interest because of its success in satisfying the patient's needs. These procedures could cause foreign body reaction, scarring, deformity, ulceration, and sexual dysfunction.

References

1. Bjekic M (2013) Artificial Penile Nodules: a Case Series of Three Patients. *Serbian J Dermatol Venereol* 5: 165-170.
2. Al-Ansari AA, Shamsodini A, Talib RA, Gul T, Shokeir AA (2010) Subcutaneous cod liver oil injection for penile augmentation: review of literature and report of eight cases. *Urology* 75: 1181-1184.
3. Silberstein J, Downs T, Goldstein I (2008) Penile injection with silicone: case report and review of the literature. *J Sex Med* 5: 2231-2237.
4. Wassermann RJ, Greenwald DP (1995) Debilitating silicone granuloma of the penis and scrotum. *Ann Plast Surg* 35: 505-509.
5. Arthaud JB (1973) Silicone-induced penile sclerosing lipogranuloma. *J Urol* 110: 210.
6. Yacobi Y, Tsivian A, Grinberg R, Kessler O (2007) Short-term results of incremental penile girth enhancement using liquid injectable silicone: Words of praise for a change. *Asian J Androl* 9: 408-413.
7. Cavalcanti AG, Hazan A, Favorito LA (2006) Surgical reconstruction after liquid silicone injection for penile augmentation. *Plast Reconstr Surg* 117: 1660-1661.
8. Gurdal M, Karaman MI (2002) An unusual case of penile augmentation: subcutaneous stone implantation. *Urology* 59: 445.