



ORIGINAL ARTICLE

Epidemiological, Clinical and Scanographic Aspects of Zygomatic Arch Fractures at Owendo University Hospital

Makungu AP*, Obele Okanga MA, Moubissa D and Late SR

Department of Stomatology and Maxillofacial Surgery, Owendo University Hospital, Gabon



*Corresponding author: Alain Patrick Makungu, Department of Stomatology and Maxillofacial Surgery, Owendo University Hospital, Libreville, Gabon

Summary

Introduction: Fractures of the zygomatic arch are responsible for anatomical changes with functional and aesthetic repercussions. Diagnosis is clinical and paraclinical. The aim of this study was to determine the epidemiological, clinical and scanographic aspects of these fractures.

Patients and methods: This was a retrospective, descriptive, analytical, cross-sectional, monocentric study conducted from 2016 to 2022, covering zygomatic arch fractures admitted to the Department of Stomatology and Maxillofacial Surgery. All radiologically confirmed zygomatic arch fractures were included. Patients with incomplete records and facial fractures without zygomatic arch fractures were excluded. Fracture features were classified according to the Özyazgan and Jung classifications. The following parameters were studied: age, sex, profession, mode of recruitment, etiology, mechanism, time to consultation, functional and physical signs, CT findings.

Results: 44 cases were collected. The mean age was 34 ± 12.9 years. Men accounted for 84% of cases. 59% of patients came from the emergency department. MVA was observed in 60% of cases, and the mechanism was direct in 88%. Trismus was found in 93.2%, facial pain in 95.5%, facial asymmetry in 98% and preauricular depression in 75%. CT scans were performed in 100% of cases, combined zygomatic arch fractures accounted for 82% and isolated fractures for 8%.

Conclusion: Fractures of the zygomatic arch are frequent, affecting young males. Road accidents are the main etiology. Limited mouth opening and preauricular depression are the signs of appeal. CT is the reference examination.

Keywords

Fracture, Zygomatic arch, Epidemiology, Diagnosis, CT scan

Introduction

The zygomatic arch is a long, thin, cylindrical bridge-like bony structure which plays a major role as a lateral bumper for the face [1]. As a result, it is frequently subject to maxillofacial trauma, leading to bone continuity fractures. These fractures are generally the result of high and low speed forces or impacts on the lateral part of the face [2].

Fractures of the zygomatic arch are common in young males, and road accidents are the main cause of these fractures [3]. Zygomatic arch fractures frequently occur as part of zygomatico-maxillary complex fractures, which account for around 25% of all facial fractures, but isolated zygomatic arch fractures account for 10% of all malar fractures and 5% of all facial fractures [4,5].

Diagnosis is straightforward, suspected clinically in the presence of post-traumatic facial asymmetry, and confirmed by maxillofacial computed tomography (CT), which is then used to search for associated lesions and the characteristics of the fracture line. For certain complex fractures, CT is taking on an increasingly important role as a means of better assessment [6-8].

The aim of this study was to determine the clinical and CT aspects of zygomatic arch fractures at Owendo University Hospital.

Patients and Method

This was a retrospective, descriptive, analytical, cross-sectional, monocentric study conducted over a period of 06 years, covering all maxillofacial trauma

patients with a fracture of the zygomatic arch who were admitted Department of Stomatology and Maxillofacial Surgery at the Centre Hospitalier Universitaire d'Owendo (CHUO). All radiologically confirmed cases of zygomatic arch fractures hospitalized in the department and with a complete file were included. Patients with incomplete records were not included in our study. Patients with maxillofacial trauma without CT fracture of the zygomatic arch.

In our study, we used two classifications. The classification of zygomatic arch fractures proposed by Özyazgan, et al. [9], and the classification of isolated zygomatic arch fractures proposed by JUNG, et al. [10].

Data were collected on a form from: Hospitalization records, consultation and hospitalization registers, and from the operating theatre intervention register.

The parameters studied were: Age, sex, profession, mode of recruitment, etiology, mechanism, consultation time, functional and physical signs, CT scan results.

Data analysis was performed using SPSS (Statistical Package for the Social Sciences) version 23 and Word and Excel 2019 software. Qualitative variables were expressed as effectives and percentages, and quantitative variables as means, minima and maxima. The association between certain variables was analyzed using the chi-square test with Yates correction and was deemed statistically significant for a value of $P < 0.5$.

Our search engines were: Pub Med, Google scholar, RefSeek, National Library of Medicine (NLM).

Results

Epidemiological aspects

44 patients were enrolled during the study period. The

mean age was 34 ± 12.9 years, with extremes of 13 and 68 years. There were 37 men (84.08%) and 7 women (16%).

Employees represented 50% of cases, the unemployed 22% of patients, students/pupils 22% of cases and retired people 6% of cases. 59.1% of cases came from the CHUO emergency department (Figure 1). There were no cases in June (Figure 2). Public road accidents caused 59.1% of fractures, domestic accidents 16%, fights/aggressions 13.41% and work-related accidents 7%. The mechanism of RTA was auto-pedestrian in 57.6% of cases and auto-auto in 27% (Table 1).

Clinical and paraclinical aspects

38.63% of cases consulted a doctor within the first six hours of trauma (Figure 3). Facial pain was present in 95.5% of cases, and opening limitation was observed in 93.5% of patients (Figure 4). Facial asymmetry (88.1% of cases), preauricular depression (75.0% of cases) and exquisite pain (84.1% of cases) were the most frequent clinical signs (Table 2).

CT scans were performed in 100% of cases. Combined zygomatic arch fractures accounted for 82% of cases, and isolated zygomatic arch fractures for 18%.

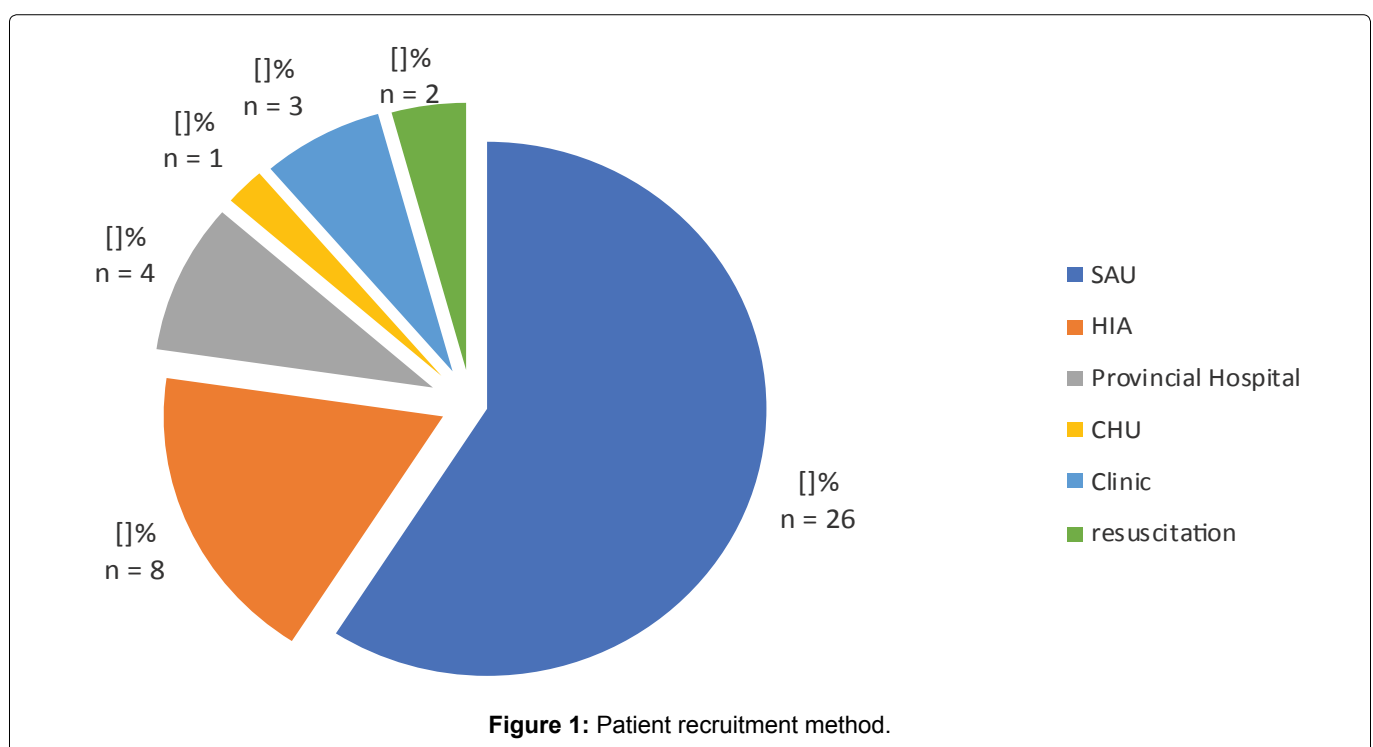
Subtype IV isolated zygomatic arch fractures accounted for 37.5% of cases (Table 3). The fracture line was located on the right in 52.3% of cases, on the left in 31.8% and bilateral in --16%.

Tegument involvement accounted for 81.81% of associated lesions (Table 4).

Discussion

Epidemiological aspects

Fractures of the zygomatic arch mainly concern



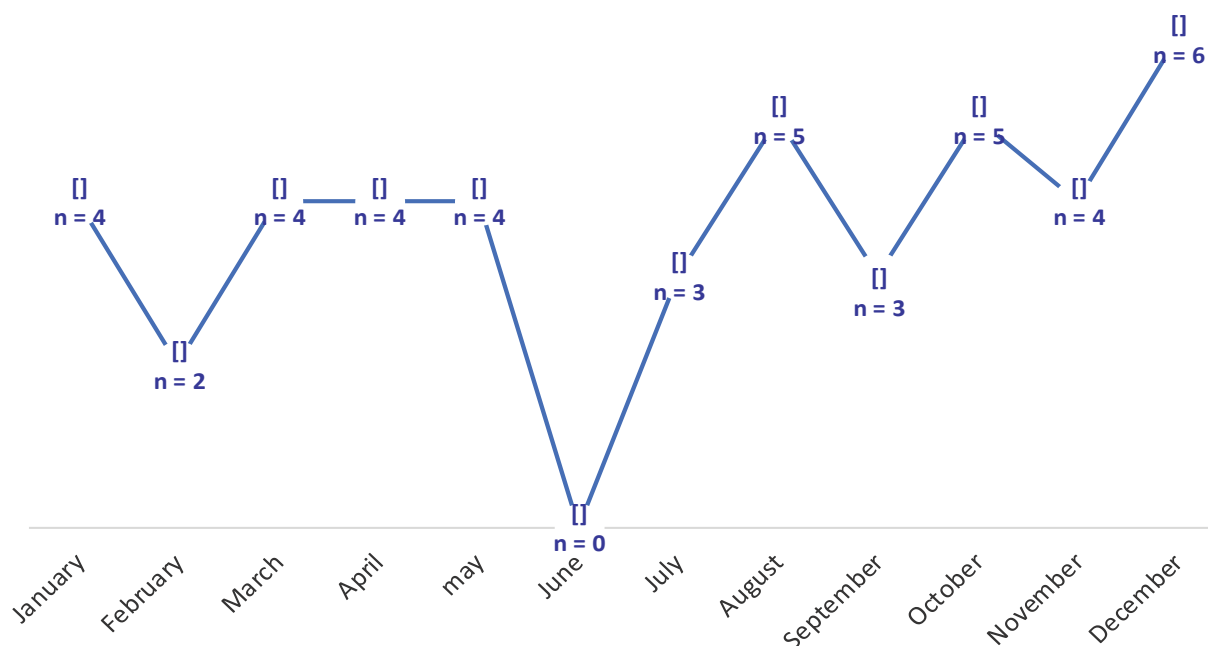


Figure 2: Monthly patient distribution.

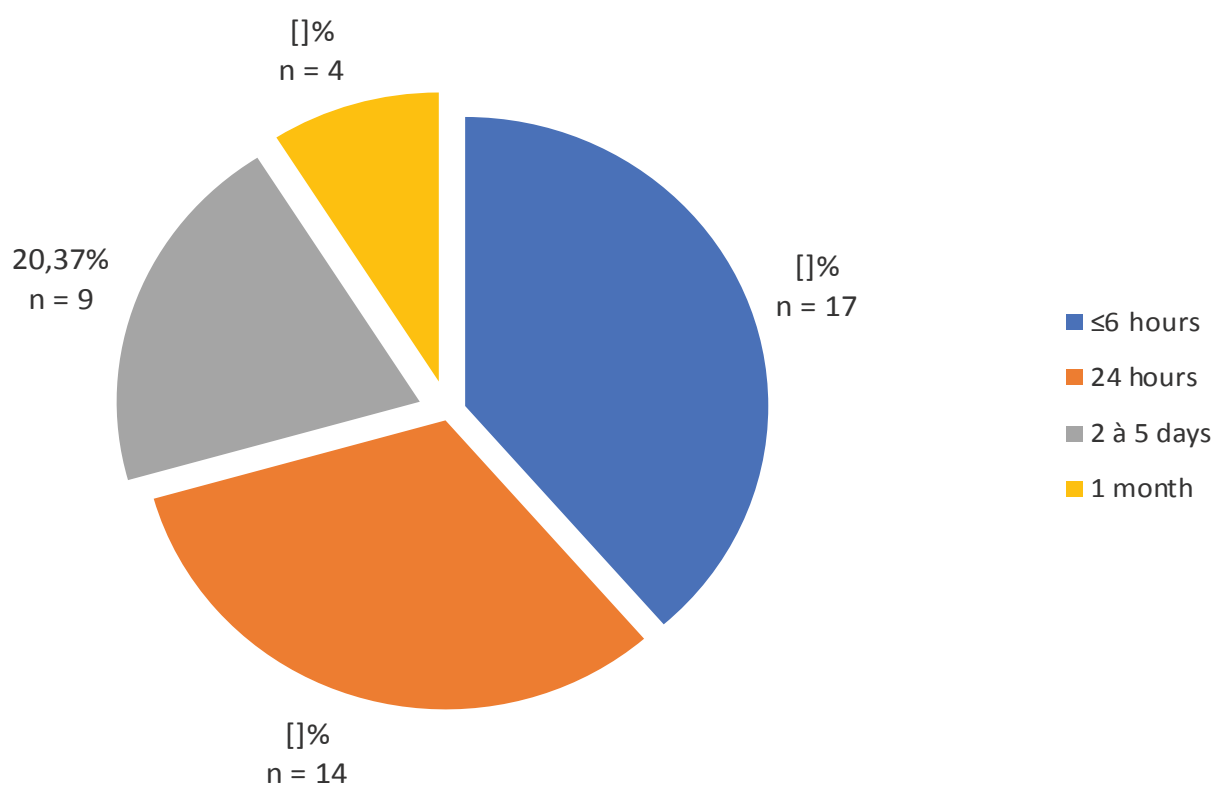


Figure 3: Breakdown of patients by length of consultation.

Table 1: Breakdown of patients by MVA mechanism.

Mechanism	N (44)	(%)
Auto-pedestrian impact	15	57.6
Auto shock	7	27
Car-bike collision	2	7.6
Motocycle-obstacle collision	2	7.6

young subjects, with an average age of 34 ± 12.9 years, which is in line with the work of Kim J, et al. [11] and Sanago S, et al. [12], in which the average age is 26 years, or Cho J, et al. [13].

The male population is the most affected by these fractures, as reported in the study by Jung S, et al. [10] with a sex ratio of 4, and that by Sanago S, et al. with a sex ratio of 3 [12].

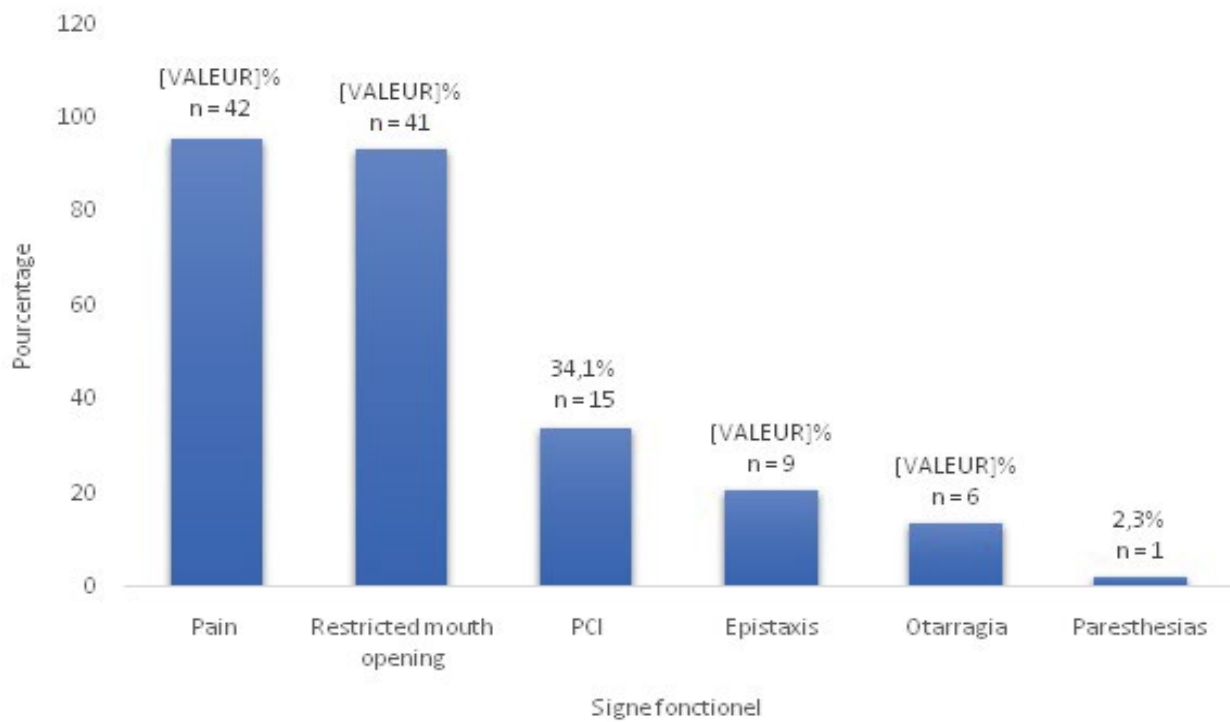


Figure 4: Distribution of patients' functional signs.

Table 2: Distribution of patients according to physical signs.

Physical signs exobuccal	n	(%)
Trismus	39	88.6
Exquisite pain	37	84.1
Pre-ear indentation	33	75
Palpebral edema	26	59.1
Cheekbone edema	25	56.8
Bone mobility	25	56.8
Ecchymosis	24	54.5
Wound	24	54.5
Dermabrasion	19	43.2
Hemifacial edema	19	43.2
Cheekbone effacement	17	38.6
Peri-auricular edema	16	36.4
Deformity	12	27.3
Hypoesthesia	12	27.3
Hematoma	9	20.5

Table 3: Distribution of patients according to subtype of isolated zygomatic arch fractures.

Fracture subtype	n	(%)
Type I	1	12.5
Type II	1	12.5
Type III	0	0
Type IV	1	12.5
Type V	2	25
Type VI	3	37.5

Table 4: Distribution of patients according to associated facial lesions.

Variables	Value(s)
Involvement of the integuments	81.81%
Cerebral hematoma	22.72%
Mandible fracture	13.63%

This average age and male predominance can be explained by the fact that the country's population is very young and engages in physical and violent activities.

In a third of cases, patients were transported by ambulance. This demonstrates the poor communication in the care of trauma victims at the scene of the accident, and the difficulty the population has in reaching emergency units in our country.

In terms of monthly trauma frequency, December and, to a lesser extent, August and October are the most accident-prone months. This corresponds to the period of social unrest and large-scale crowd movements.

In the vast majority of cases, the impact is direct, reflecting the zygomatic arch's exposure to violent contact and its role as a lateral shock absorber for the face.

In this study, the dominant etiology was a public road accident, which confirms the work of Kim J, et al. [11], Orabona, et al. [14], Sanago S, et al. [12], but contradicts the studies of Czerwinski M, et al. [2] where brawls and assaults are the dominant etiologies. This contrast can be explained by the quality of the road network and the lack of respect for the rules of the road in our country.

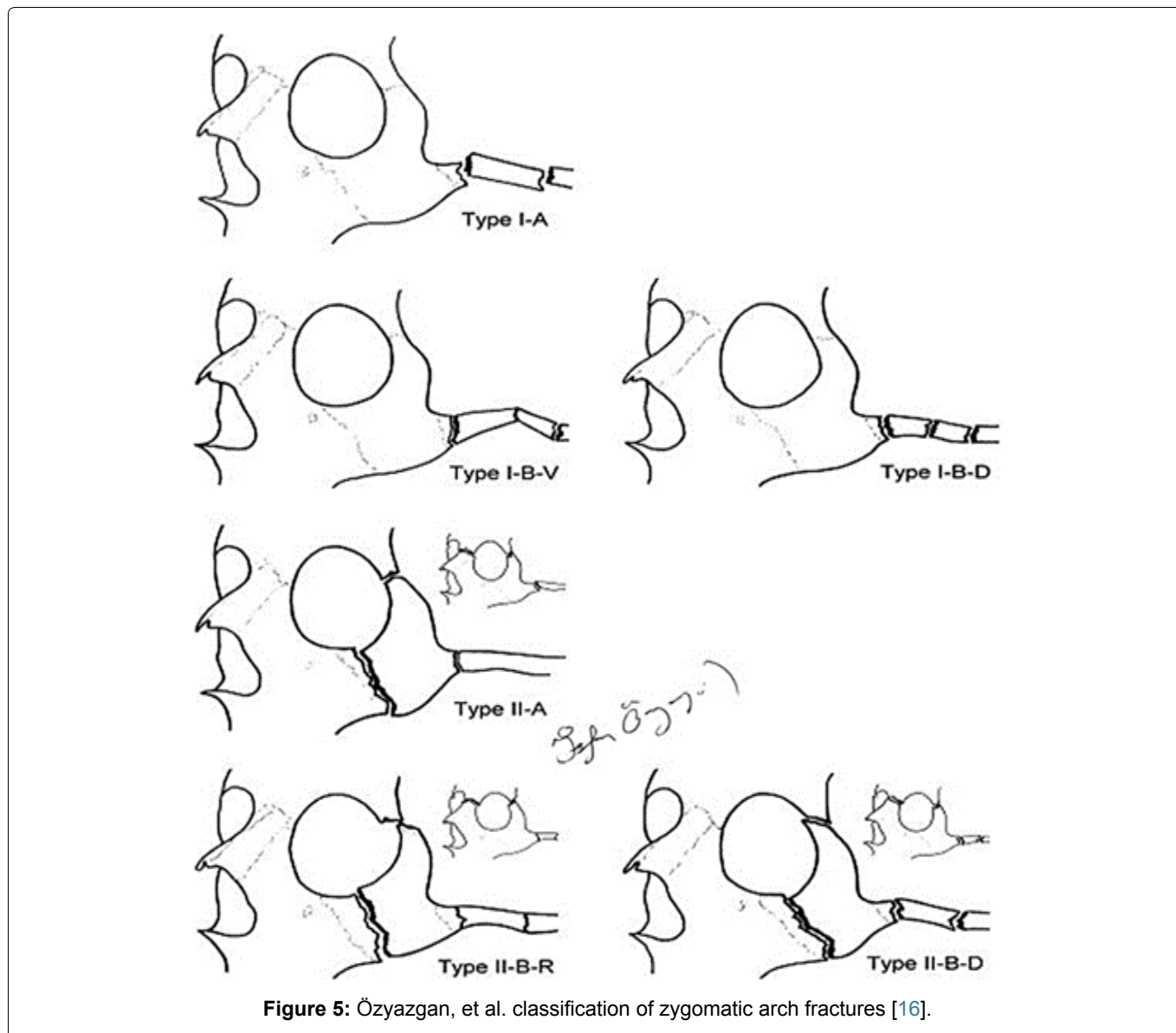


Figure 5: Özyazgan, et al. classification of zygomatic arch fractures [16].

However, a study carried out in the city of Montreal shows a 50% rate of zygomatic arch fractures following fights and assaults, demonstrating the opposite.

Clinical and paraclinical aspects

The average consultation time in our series was 2 to 3 days, i.e. 38.63% of cases. Our data contrast with those of Diallo, et al. in Mali, where most patients (66.2%) consulted on the day of the trauma. This difference can be explained by the fact that, in our context, patients first stay in the ICU or intensive care unit before consulting the stomatology and maxillofacial surgery department of the CHUO.

Mouth opening limitation and facial pain were the main functional signs, with frequencies in excess of 90%. Our data corroborate those of Do Santos Zounon, et al. and Moussa, et al. where these functional signs account for over 90% [12,15].

Morphologically, facial asymmetry and preauricular depression were the main signs, with frequencies of over 80%. Our results corroborate those of literature, such as

Jung S, et al. Rosselo, et al. Kim J, et al. where these morphological signs are in the foreground [10,11,16].

Diagnosis of zygomatic arch fractures always requires CT scanning, as shown in the studies by Jung S, et al. [10], Kim J, et al. [11] and Valdes, et al. [17], where CT was performed in all patients in these studies. CT is the reference examination, enabling us to establish classifications that are highly useful for both diagnostic and therapeutic purposes.

We have 06 classifications of zygomatic arch fractures at our disposal, of which the most clinically and paraclinically useful are:

The classification of Özyazgan, et al. [9], which divides fractures of the zygomatic arch into two groups (Figure 5), and the classification of Jung, et al. [10], which proposes a classification of isolated fractures of the zygomatic arch (Figure 6) are the classifications we have used, as they are easy to interpret. However, there is also the classification of Kim Jaye, et al. [11], which offers a very detailed description of isolated zygomatic arch fractures, zygomatic-maxillary complex

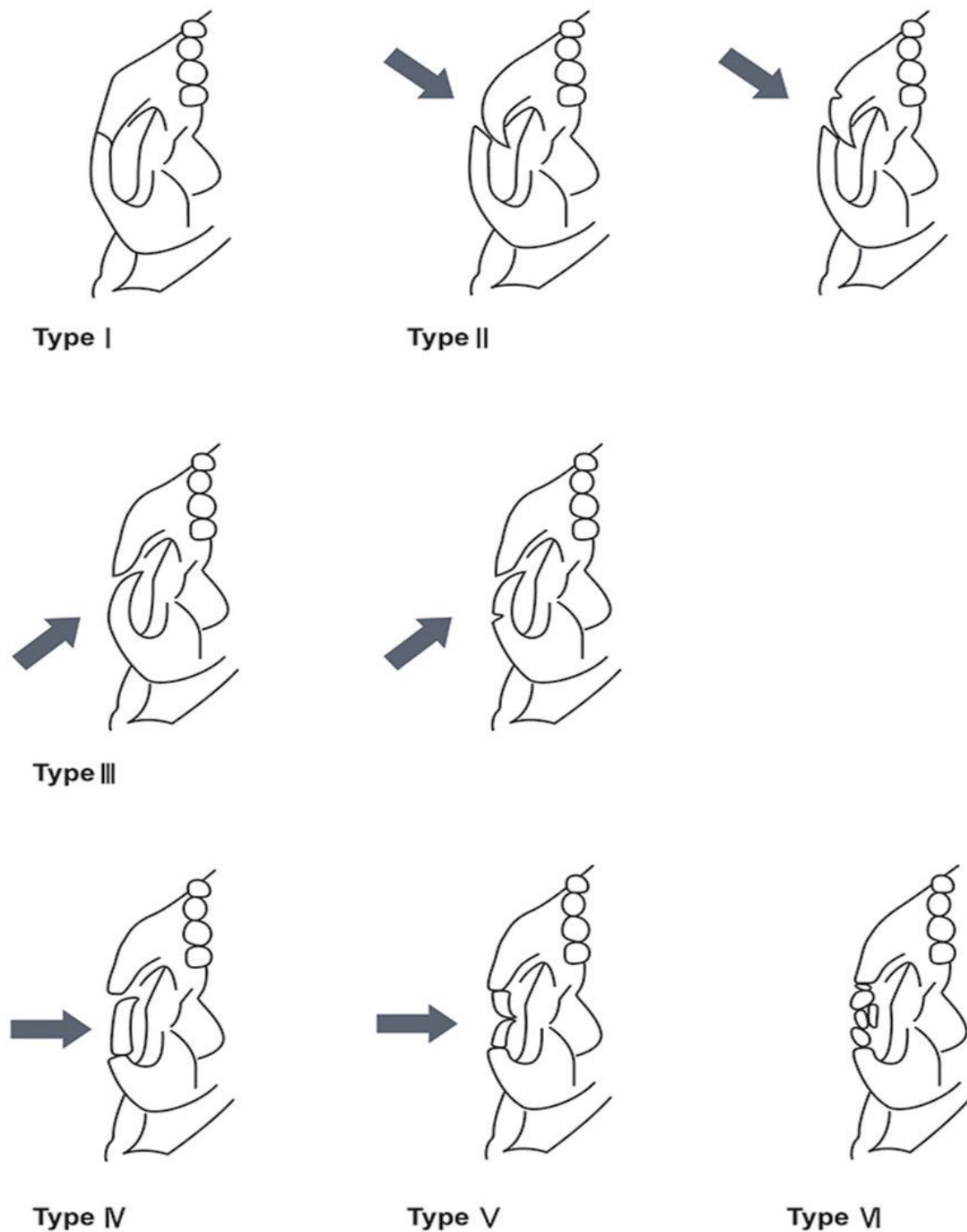


Figure 6: Nam and Jung classification of isolated zygomatic arch fractures (the arrow represents the force vector of the lesion) [12].

fractures involving the zygomatic arch and comminuted zygomatic arch fractures (Figure 7 and Figure 8), as well as the classification of Valde R, et al. [17] and Honig, et al. [7]. In our study, combined zygomatic arch fractures accounted for 82% of cases, and isolated zygomatic arch fractures for 18%. Our work is similar to that of Ozyazgan, et al. who found 90.68% combined fractures and 9.32% isolated fractures. But also, those of Kim J, et al. whose combined fractures accounted for 78% of

cases and isolated fractures of the zygomatic arch for 22% [9].

Typing of isolated zygomatic arch fractures revealed that the most predominant subtype was subtype VI with 37.5% of cases, followed by subtype V with 25% of cases. These results differ from those reported in the literature. Thus, for Jung, et al., the majority subtype is subtype V with 56% [10]. In the study by Valdes,

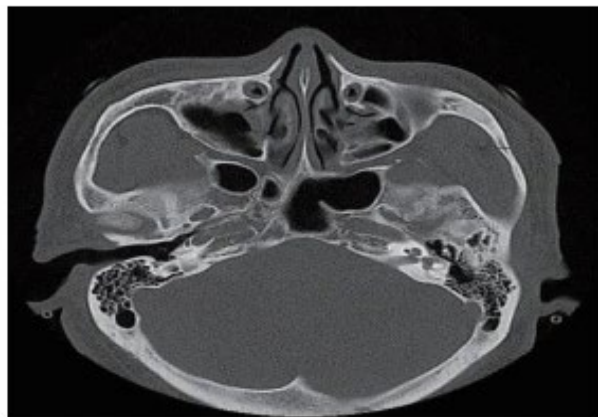
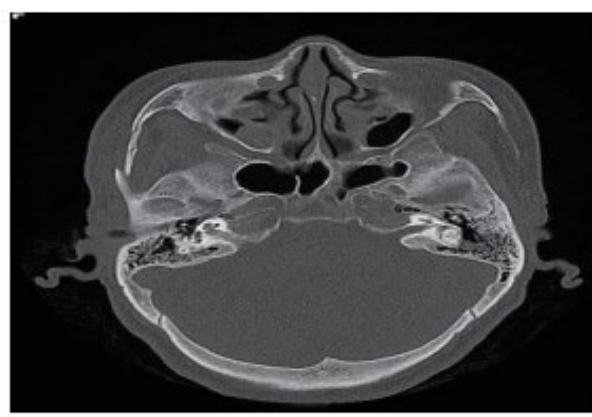
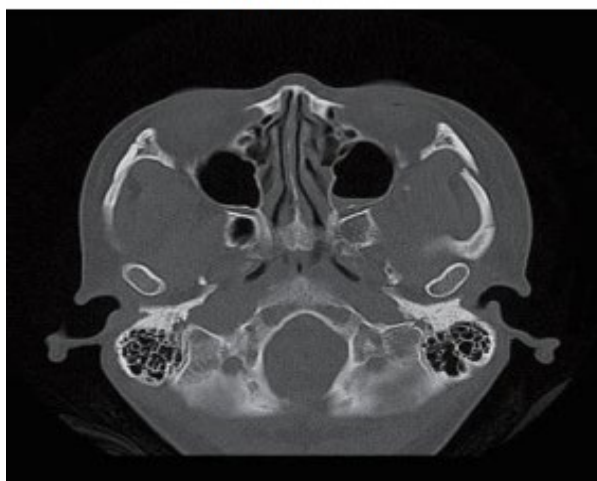
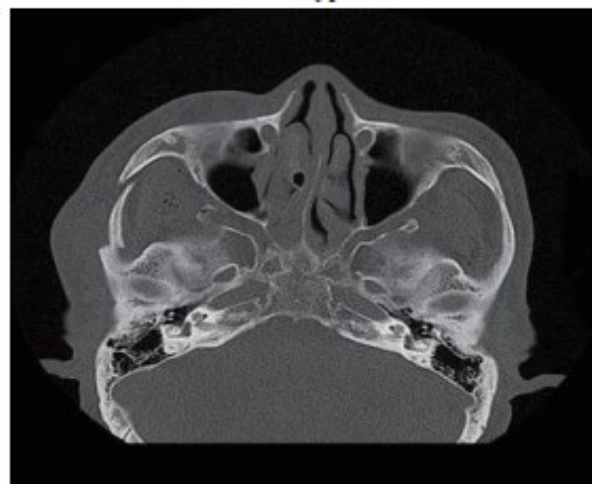
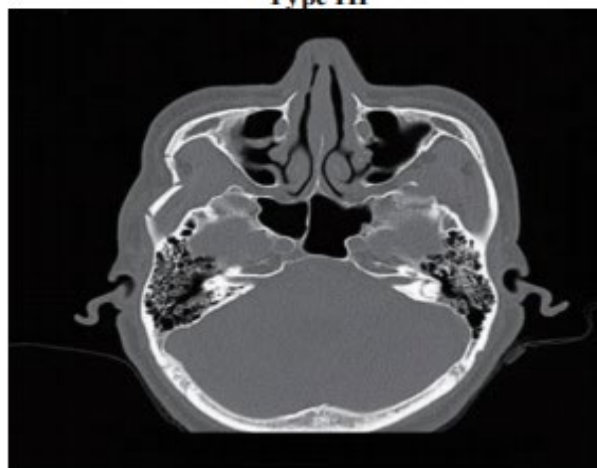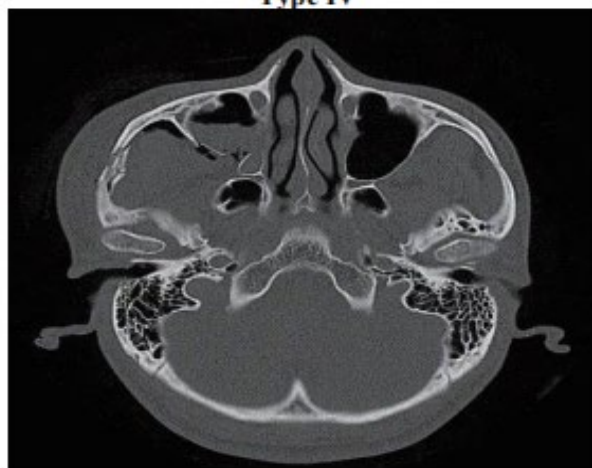**Type I****Type II****Type III****Type IV****Type V****Type VI**

Figure 7: Maxillofacial CT scan in coronal section showing the different types of isolated fractures of the zygomatic arch according to the classification of Jung, et al. 2021 [12].

et al., the most frequent subtype is subtype IV with 56% [17]. And in the study by Kim J, et al., the most frequent subtype is IIB [11]. The literature testifies to the variability of occurrence of the different subtypes of zygomatic arch fracture in trauma.

With regard to combined fractures of the zygomatic arch, of which Lefort 3 fractures represent 44.44% of

cases and malar fractures 33.33%, our results differ from those of the study by Özyazgan, et al. where malar fractures predominate with 71.17% and Lefort III fractures represent 19.51%, whereas in the study by Ragupathy, et al., Lefort III fractures predominate with 51.42% of cases [9,18].

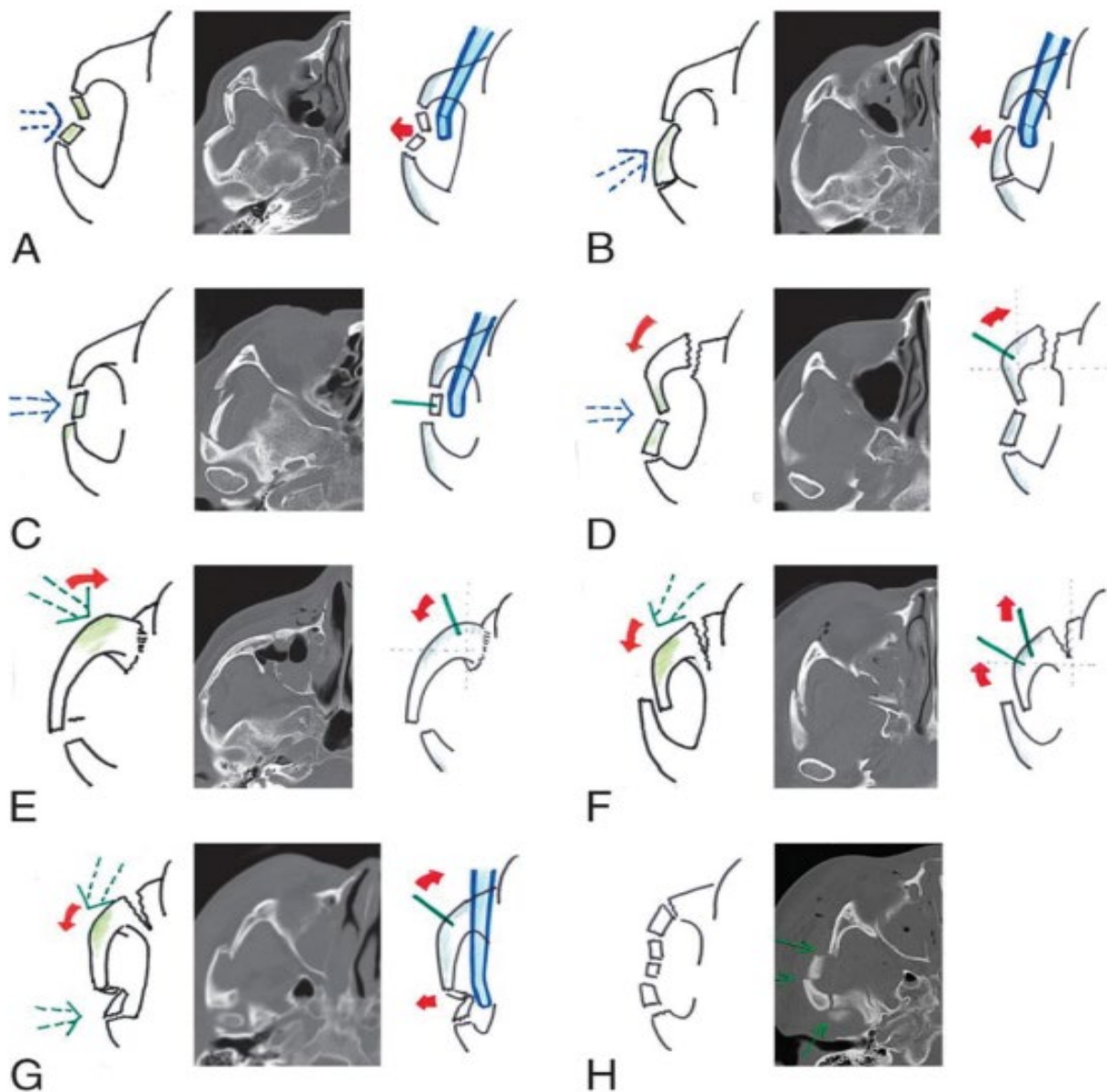


Figure 8: Classification of zygomatic arch fractures and their reduction (arrow Blue dotted line- traumatic force; red arrow- rotation vector; green line- pin inserted on zygomatic segment; blue device- Dingman elevator). A: subtype 1A; B: Subtype 1B; C: Subtype 1C; D: Subtype 2A; E: Subtype 2B; F, Subtype 3A; G: Subtype 3B; H: subtype 4 [11].

Conclusion

Fractures of the zygomatic arch are common in young males, with road traffic accidents being the main cause. Limited mouth opening, preauricular depression, facial asymmetry and facial pain are the warning signs of a zygomatic arch fracture. CT is the gold standard for confirming the diagnosis, establishing classifications, and identifying associated lesions.

References

- Glicenstein J, Ombrédanne L (2015) Pediatric and plastic surgeon. In: *Annales de chirurgie plastique esthétique*. Elsevier Masson, 87-83.
- Czerwinski M, Lee C (2006) The rationale and technique of endoscopic approach to the zygomatic arch in facial trauma. *Facial Plast Surg Clin North Am* 14: 37-43.
- Obuekwe O, Owotade F, Osaiyuu O (2005) Etiology and pattern of zygomatic complex fracture: A retrospective study. *J Natl Med Assoc* 97: 992-996.
- Kiwanuka E, Smith SE, Frates MC, Cateson EJ (2013) Use of high-frequency ultrasound guidance for intraoperative zygomatic arch fracture reduction. *J Craniofac Surg* 24: 2036-2038.
- Baek SH, Cho IS, Chang YI, Kim MJ (2007) Skeletodental factor affecting chin point deviation in female patients with class III malocclusion and facial asymmetry: A three-dimensional analysis using computed tomography. *Oral Surg Oral Med Oral Pathol Oral Radiol Endod* 104: 628-639.
- de Santana Santos T, da Rocha Neto AM, Medeiros Jr R, Antunes AA, de Oliveira DM (2011) Treatment of zygomatic arch fracture with lag screws. *J Craniofac Surg* 22: 1468-1470.
- Hönig JF, Merten HA (2004) Classification system and

- treatment of zygomatic arch fractures in the clinical setting. *J Craniofac Surg* 15: 986-989.
8. Wang D, Smit R, Liu B, Lewis C (2022) Stabilization of an isolated zygomatic arch fracture with a ballooned Foley catheter. *Advances in Oral and Maxillofacial Surgery* 7: 100299.
 9. Özyazgan I, Günay GK, Eskitaşçıoğlu T, Ozköse M, Coruh A (2007) A new proposal of classification of zygomatic arch fractures. *J Oral Maxillofac Surg* 65: 462-469.
 10. Jung S, Yoon S, Nam SH (2022) Proposal for a modified classification of isolated zygomatic arch fractures. *Arch Craniofac Surg* 23: 111-118.
 11. Kim J, Kim S, Chung S, Chung YK (2014) Zygomatic arch fracture: A new classification and treatment algorithm with epidemiologic analysis. *J Craniofac Surg* 25: 1389-1392.
 12. Sanogo S, Kouma A, Cissé I, Guindo I, Diarra O, et al. (2022) Epidemiological and CT profile of post-traumatic maxillofacial fractures in Mopti, Mali. *Pan Afr Med J* 41: 1309.
 13. Cho J, Kim Y, Choi Y (2021) Three-dimensional analysis of facial asymmetry after zygomaticomaxillary complex fracture reduction: A retrospective analysis of 101 east asian patients. *Arch Craniofac Surg* 22: 148-153.
 14. Orabona GDA, Abbate V, Maglitto F, Committeri U, Improta G, et al. (2019) Postoperative management of zygomatic arch fractures: In-house rapid prototyping system for the manufacture of protective facial shields. *J Craniofac Surg* 30: 2057-2060.
 15. Moussa M, Kaka HA, Bancole PS, Kone R, Sidibe O (2020) Craniofacial trauma and lack of safety helmet among motorcycle drivers in niamey. *Health Sciences and Disease* 21: 73-76.
 16. Rosello EG, Granado AMQ, Garcia MA, Martí SJ, Sala GL, et al. (2020) Facial fractures: Classification and highlights for a useful report. *Insights Imaging* 11: 49.
 17. Reyes JMV, Ocampo SZ (2021) Functional classification of isolated zygomatic arch fracture: New proposal. *J Craniofac Surg* 32: 757-758.
 18. Ragupathy K, Pasupathy S (2017) An epidemiological study of zygomatic complex and zygomatic arch fractures in a tertiary hospital: A retrospective study. *J Oral Med Oral Surg Oral Pathol Oral Radiol* 3: 1-4.