



CASE REPORT

Decompression of Large Keratocystic Odontogenic Tumor: Review of Literature and Case Report

Mohamed Elseyoufi, BDS, MBBS, MSc-OMS, FRACDS^{1*}, Ayman Hasan Alrabiaa, BDS² and Peter Tsakiris, BDS, MSc, FCD, MD³

¹Oral and Maxillofacial Surgery Consultant, Najran General Hospital, Najran, Saudi Arabia

²Ayman Hasan Alrabiaa, Dental Intern Doctor, Najran General Hospital, Najran, Saudi Arabia

³Oral and Maxillofacial Surgery Consultant, Prince of Wales Hospital, Sydney, NSW, Australia

*Corresponding author: Mohamed Elseyoufi, BDS, MBBS, MSc -OMS, FRACDS, Post-Grad Diploma- Implants, Oral and Maxillofacial Surgery Consultant, Najran General Hospital, Najran, 66241, Saudi Arabia, Tel: +966557907178



Abstract

Introduction: Decompression followed by enucleation of Keratocystic odontogenic tumour (KCOT) is a recommended conservative approach for large KCOT to prevent injury to the surrounding vital structures, pathological fracture of the mandible and radical resection surgery. On the other hand, this approach necessitates multiple surgical procedures and prolonged follow-up which depends on the patient's compliance and may increase the risk of infection.

Case report: A 42-year-old male presented with large right mandibular angle KCOT associated with impacted wisdom tooth. Decompression, incisional biopsy, and extraction of wisdom tooth were performed under Local anaesthesia. CBCT, 3 and 6 months post-operatively demonstrated obvious reduction of cystic cavity which allowed for enucleation of KCOT followed by Carnoy's solution application under GA with minimal complications.

Conclusion: Decompression of large KCOTs followed by enucleation with peripheral ostectomy or chemical therapy is viable treatment option to avoid invasive resection surgical procedure.

for periodic follow-ups [4]. Decompression of KCOT is a simple method for stimulating new bone formation due to the reduction in cystic pressure by creating a hole that connects the cystic cavity with the oral cavity which allows cystic fluid to evacuate [5]. Therefore, decompression should be considered when KCOT enlarges and approaches vital structures or weakens the jaw.

Treatment options for KCOT should take into account a variety of criteria, including the patient's age, the size and location of the cyst, soft tissue involvement, past treatment history, and the histological variant of the lesion [6]. The objective is to select the modality of treatment that eliminates the lesion with the least possibility of morbidity and recurrence risk.

Large multinucleated KCOT that include soft tissue involvement and cortical bone perforation, as well as lesions that have already recurred after receiving conservative therapy, should be resected to the adjacent anatomic boundary [7]. On the other hand, it has been reported that decompression of large KCOT that have not yet perforated the cortical bone followed by peripheral ostectomy with or without chemical therapy has had positive results [8].

Introduction

The keratocystic odontogenic tumour (KCOT) is a benign and locally aggressive tumour [1] derived from dental lamina [2]. Currently, enucleation and decompression are the two common treatment options [3]. Due to the problems associated with radical treatment, decompression has been proposed as a more conservative treatment, despite the need

The Case Report

A 42-year-old male was referred to the Oral and maxillofacial surgery department at Najran general



Citation: Elseyoufi M, Alrabiaa AH, Tsakiris P (2023) Decompression of Large Keratocystic Odontogenic Tumor: Review of Literature and Case Report. Res Rep Oral Maxillofac Surg 7:071. doi.org/10.23937/2643-3907/1710071

Accepted: April 26, 2023; **Published:** April 28, 2023

Copyright: © 2023 Elseyoufi M, et al. This is an open-access article distributed under the terms of the Creative Commons Attribution License, which permits unrestricted use, distribution, and reproduction in any medium, provided the original author and source are credited.

hospital (Saudi Arabia) following an accidental finding of a large right mandibular angle cystic lesion during a routine check by his dentist. He smokes a pack of cigarettes per day for the last 25 years, otherwise, he is fit, healthy and not on any regular medication. On examination, there was no facial swelling, Inferior alveolar and lingual nerves were intact bilaterally. There was no evidence of intra-oral swellings or sinus tract. Teeth at quadrant four are vital and stable with

no mobility. CBCT demonstrated an inverted impacted 48 associated with a unilocular, well-demarcated radiolucent lesion, extending from 46 to the right mandibular angle with a size of $36 \times 30 \times 16$ mm (Figure 1 and Figure 2). There was no obvious root resorption, and the inferior alveolar canal was at the Bucco-inferior border of the lesion. Aspiration revealed a keratin content of the cystic lesion.

The patient consented to the extraction of 48,

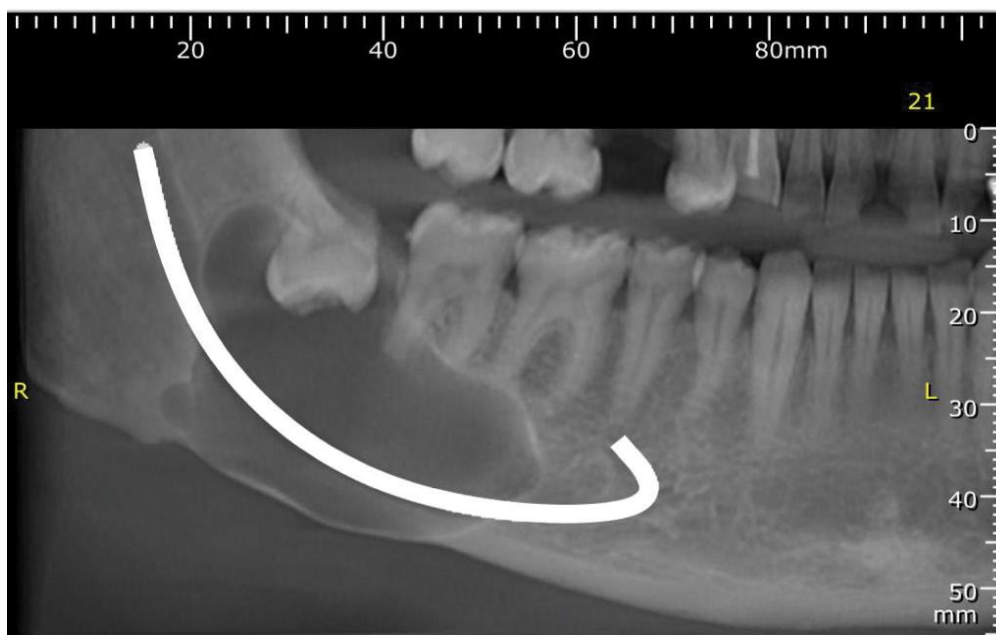


Figure 1: Preoperative CBCT.

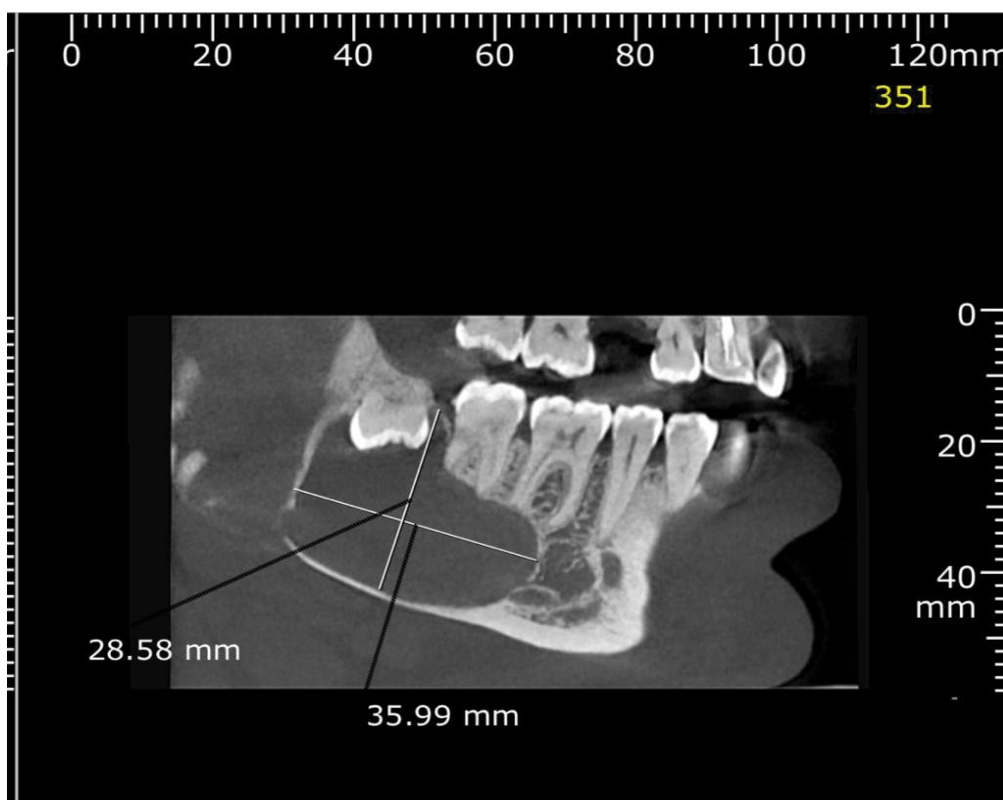


Figure 2: Preoperative CBCT.

decompression and incisional biopsy. Surgical removal of 48, decompression using a nasopharyngeal airway tube (NPT) and incisional biopsy were performed under Local anaesthetic without complications. The histopathology confirmed ortho-keratinized OKC. CBCT was done 3 months postoperatively (Figure 3), demonstrating bone deposition at the periphery of the cystic lesion. The size of the lesion decreased to 30 × 23 × 13 mm. Therefore, the NPT was replaced with a shorter one. CBCT, 6 months post-operatively (Figure 4) revealed a further decrease in the lesion size to 26 × 18 × 11 mm. This was followed by the enucleation of the lesion under GA and the application of Carnoy's solution. Postoperatively, the patient complained of right lower lip paraesthesia which is completely resolved 6 weeks later. Follow-up was arranged for the patient at 3 and

6 months for further radiological imaging to assess the progress of healing of the cystic cavity and the possibility of recurrence.

Discussion

KCOT is a common odontogenic entity that requires specific treatment due to its aggressive behaviour and propensity to recur [9], with a male-to-female ratio of 2:1 and a predilection for the posterior mandible, which is involved in 65% to 83% of cases. KCOTs are most prevalent in the second, third, and fourth decades of life (54.2%) [10]. KCOT has a scalloped contour on radiographs and appears as uni or multilocular radiolucency [11].

In contrast to typical cysts, KCOT displays distinctive growth and biological behaviour, with the growth being

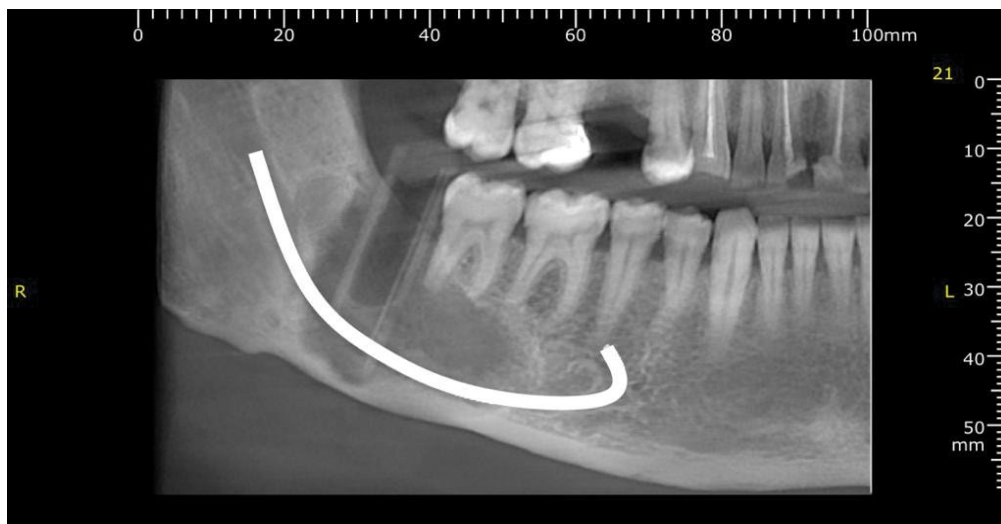


Figure 3: 3-month postoperative CBCT.

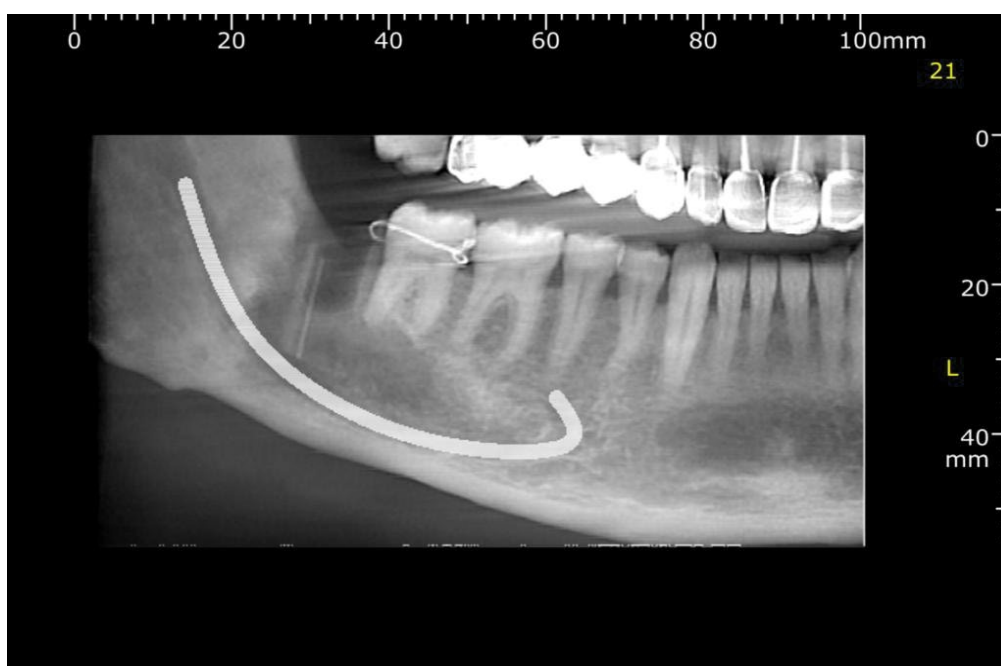


Figure 4: 6-month postoperative CBCT.

caused by the active proliferation of the epithelial lining. The majority of commonly occurring cysts grow due to the osmotic pressure of the cystic fluid. The expansion of the buccal and lingual cortical plates is caused by this expansile type of growth. KCOT, on the other hand, behaves like a benign tumour that grows through extension rather than expansion. The osmotic pressure of the cystic fluid is quite low with KCOT, therefore, the extension follows the route of least resistance which is the cancellous bone, consequently, KCOT grows antero-posteriorly, with no evidence of cortical expansion in the early stages [12,13].

Jaw cysts can be treated surgically using one of three methods: enucleation, marsupialization, or decompression [14]. KCOTs have a high recurrence rate due to thin epithelium lining, daughter cysts, collagenase activity of the cyst and incomplete removal of cyst lining. Therefore, many surgical procedures have been attempted for the treatment of KCOTs. In the multilocular situation, a complete removal is quite difficult [15]. Some authors have suggested radical surgery, such as resection and the Brosch technique, to lower the high recurrence rate [16].

Resection of large KCOT can compromise function and aesthetics. Therefore, decompression and second-stage enucleation is the best choice when a cyst is large and close to critical anatomical structures in order to preserve the neighbouring teeth, the inferior alveolar canal, and the maxillary sinus. By releasing the intracystic pressure, the cyst's size is reduced, which can allow impacted teeth to erupt and the growth of new bone [6,14,17]. Due to the aforementioned benefits, the treatment protocol for a large KCOT has recently been modified to adopt this conservative approach [14,18]. The drawbacks of decompression include that it necessitates two surgical procedures, takes more time [8], has a higher recurrence rate than surgical resection [16], uncomfortable to patients, necessitates their compliance, and poses a danger of infection. During the decompression process, a window is maintained open by packing the cystic cavity or, more frequently, by suturing a device (tube, stent) to its periphery. This allows for the drainage of fluids out of the KCOT. In our

case, decompression was accomplished via NPT. It was founded on the rationale that releasing the intramural pressure would cause the cysts to shrink through progressive bone development from the periphery [17].

Typically, resection of KCOT is indicated for lesions that have recurred following several "conservative" surgeries and in cases where the KCOT is no longer contained in the bone where there is soft tissue involvement and perforation of the bony cortex, with the potential to affect critical structures including the orbit and lateral skull base [19].

In this case report, decompression of KCOT with subsequent enucleation and Carnoy's application was adopted choice of treatment to spare the patient the dramatic consequences of resection. Following decompression for 6 months of KCOT, there was a large reduction in cystic cavity size and obvious bone deposition at the mandibular lower border which allows for enucleation of KCOT and application of Carnoy's solution with minimal complications.

There have been various studies on the differences in recurrence based on KCOT treatment methods. Resection is the most efficient method to avoid the recurrence of KCOT, however, this is a very invasive surgical operation. Simple enucleation was reported to have a recurrence rate of 17% to 56% in a review study of KCOT by Blanas, et al. [20]. The likelihood of a KCOT simple enucleation recurring is very high. However, there are numerous studies indicating a low recurrence rate after decompression following enucleation of OKC with peripheral ostectomy or application of Carnoy's solution (0-8.7%) [6,14].

Conclusion

Decompression of large KCOTs followed by enucleation with peripheral ostectomy or chemical therapy is viable treatment option to avoid invasive resection surgical procedure.

Conflicts of Interest

All authors disclose no conflicts.

Authors Contribution

Authors	Conception and design of study/ review/case series	Acquisition of data: laboratory or clinical/ literature search	Analysis and interpretation of data collected	Drafting of article and/or critical revision	Final approval and guarantor of manuscript
Mohamed Elseyoufi	Yes	Yes	Yes	Yes	Yes
Ayman Hasan Arabia	No	Literature search	No	Drafting article	No
Peter Tsakiris	No	No	No	Critical revision	Yes

References

1. Madras J, Lapointe H (2008) Keratocystic odontogenic tumour: Reclassification of the odontogenic keratocyst from cyst to tumour. *J Can Dent Assoc* 74: 165h-165h.
2. Maurette PE, Jorge J, de Moraes M (2006) Conservative treatment protocol of odontogenic keratocyst: A preliminary study. *J Oral Maxillofac Surg* 64: 379-383.
3. Kubota Y, Imajo I, Itonaga R, Takenoshita Y (2013) Effects of the patient's age and the size of the primary lesion on the speed of shrinkage after marsupialisation of keratocystic odontogenic tumours, dentigerous cysts and radicular cysts. *Br J Oral Maxillofac Surg* 51: 358-362.
4. Brondum N, Jensen VJ (1991) Recurrences of keratocysts and decompression treatment: A long-term follow-up of forty-four cases. *Oral Surg Oral Med Oral Pathol* 72: 265-269.
5. Park SY, Shin YJ, Kim CH, Kim BJ (2015) Reconstruction of extensive jaw defects induced by keratocystic odontogenic tumor via patient-customized devices. *Maxillofac Plast Reconstr Surg* 37: 37.
6. Williams TP (1991) Surgical treatment of odontogenic keratocysts. *Oral and Maxillofacial Surgery Clinics of North America* 3: 137-154.
7. Willimas RJ, Stewart TP (2000) *Surgical Pathology In: Oral and Maxillofacial Surgery Surgical Pathology*, WB Saunders Philadelphia, 5.
8. Brondum P, Clausen N (1996) Treatment of large odontogenic keratocyst by decompression and later cystectomy: A long-term follow-up and a histologic study of 23 cases. *Oral Surg Oral Med Oral Pathol Oral Radiol Endod* 82.
9. Kolokythas A, Fernandes RP, Pazoki A, Ord RA (2007) Odontogenic keratocyst: To decompress or not to decompress? A comparative study of decompression and enucleation versus resection/peripheral ostectomy. *J Oral Maxillofac Surg* 65: 640-644.
10. Thawley SE, Panje WR, Batsakis JG (1999) *Comprehensive Management of Head and Neck Tumors*, WB Saunders, Philadelphia 2: 1556.
11. Brannon RB (1976) The odontogenic keratocyst. A clinicopathologic study of 312 cases. Part I. Clinical features. *Oral Surg Oral Med Oral Pathol* 42: 54-72.
12. Kwon HI, Lim WB, Kim JS, Ko YJ, Kim IA, et al. (2011) Odontogenic keratocyst associated with an ectopic tooth in the maxillary sinus: A report of two cases and a review of the literature. *Korean J Pathol* 45: S5-S10.
13. Cawson RA, Odell EW, Porter SR (2002) *Cawson's essential of oral pathology and oral medicine*. (8th edn), Churchill Livingstone, Edinburgh, 102-121.]
14. Kruger GO (1984) *Textbook of Oral and Maxillofacial Surgery*. (6th edn), Mosby St Louis, 255-280.
15. Jung YS, Lee SH, Park HS (2005) Decompression of large odontogenic keratocysts of the mandible. *J Oral Maxillofac Surg* 63: 267-271.
16. Farmand M, Makek M (1983) Late results following the brosch-procedure for treating large mandibular ramus cysts. *J Maxillofac Surg* 11: 211-215.
17. Thoma KH (1958) *Oral surgery*. (3rd edn), St. Louis Mosby, 1033-1036.
18. Jensen J, Sindet-Pedersen S, Simonsen EK (1988) A comparative study of treatment of keratocysts by enucleation or enucleation combined with cryotherapy. A preliminary report. *J Craniomaxillofac Surg* 16: 362-365.
19. Warburton G, Shihabi A, Ord RA (2015) Keratocystic odontogenic tumor (KCOT/OKC) - clinical guidelines for resection. *J Maxillofac Oral Surg* 14: 558-564.
20. Blanas N, Freund B, Schwartz M, Furst IM (2000) Systematic review of the treatment and prognosis of the odontogenic keratocyst. *Oral Surg Oral Med Oral Pathol Oral Radiol Endod* 90: 553-558.