



CLINICAL IMAGE

Transcranial Color-Coded Duplex Ultrasonography in the Diagnosis of Brain Aneurysm

Issac Cheong, MD^{1,2*} 

¹Department of Critical Care Medicine, Sanatorio De los Arcos, Buenos Aires, Argentina

²Argentinian Critical Care Ultrasonography Association (ASARUC), Argentina

*Corresponding author: Issac Cheong, Intensive Care Unit, Sanatorio De los Arcos, Juan B. Justo 909, CABA, Argentina, Tel: +541147784500



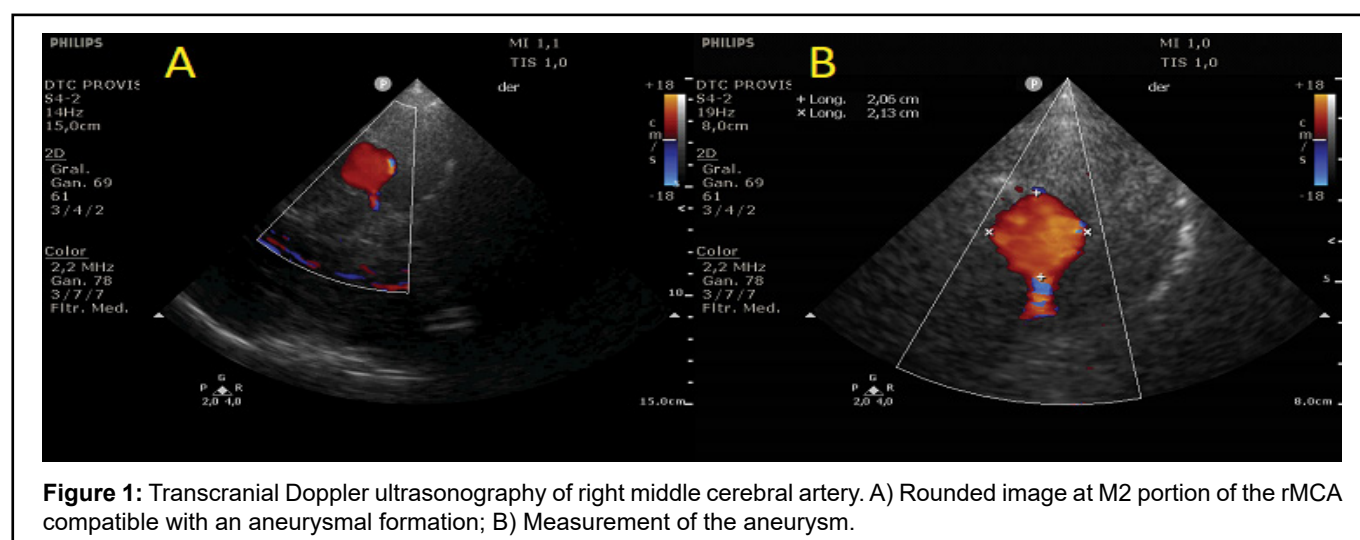
Clinical Image

A 50-year-old male with no relevant clinical history presented sudden headache accompanied by nausea, which evolved with facial paresis and drowsiness with a computed tomography (CT) showing bilateral subarachnoid bleeding, being admitted to the intensive care unit. We performed a transcranial color-coded duplex ultrasonography (TCCS) that showed the presence of a rounded image at M2 portion of the right middle cerebral artery (rMCA) that measured 20 mm × 21 mm with a positive color Doppler signal (Figure 1). CT angiography with 3D reconstruction showed an aneurysmal formation of 20 mm in the projection of

the rMCA and another small one at the level of the left middle cerebral artery (Figure 2). An angiography of intracerebral vessels confirmed a giant aneurysm of 22 mm × 25 mm at the rMCA, requiring stent placement and embolization of the aneurysm with coils. During the hospital stay, he presented vasospasm of the rMCA with a good response to treatment, evolving clinically stable, with subsequent discharge. This case demonstrates that TCCS can be useful for the diagnosis of cerebral aneurysms.

Conflicts of Interest

The author declares that he has no conflict of interest.



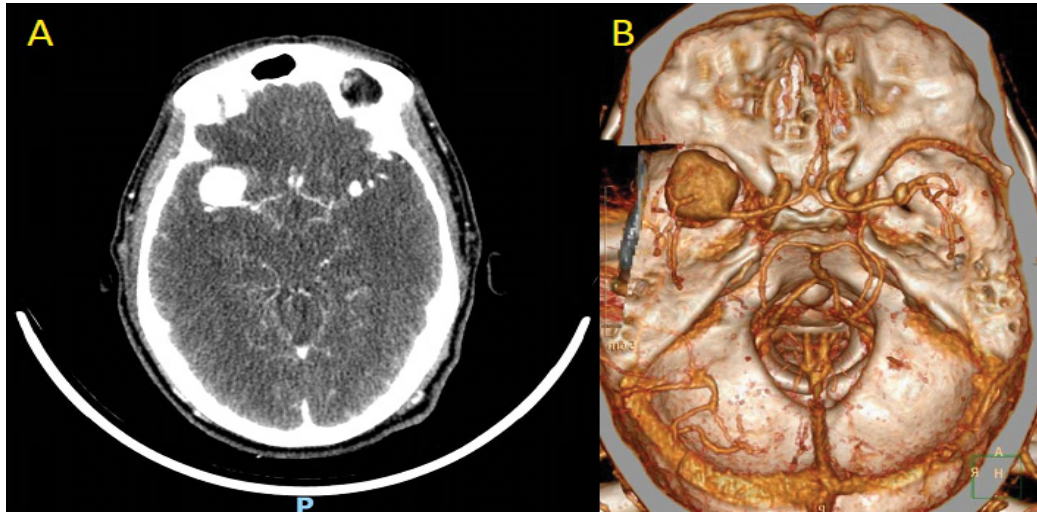


Figure 2: A) CT angiography of brain; B) CT angiography with 3D reconstruction of brain.