



IMAGE ARTICLE

Septal CRT-D Pacemaker

Sudeb Mukherjee, MBBS, MD, DM*

Department of Cardiology, Calcutta National Medical College and Hospital, India

*Corresponding author: Dr. Sudeb Mukherjee, MBBS, MD, DM, Department of Cardiology, Consultant Interventional Cardiologist, Calcutta National Medical College and Hospital, 4/28 A, Jadavgarh, Kolkata, 700078. West Bengal, India, Tel: +919163097595



Keywords

CRT -D, Fluoroscopy, Pacemaker

Manuscript

CRT-D implantation has become a standardised treatment for patients suffering from Heart Failure with reduced Ejection Fraction (HFrEF). Patients with left

ventricular ejection fraction (LVEF) below 35% along with Left Bundle Branch Block (LBBB) pattern with wide QRS duration are the most benefitted one post placement. Implantation of CRT-D needs expertise so that proper left ventricular lead placement can be done. It also depends on anatomical suitability of Coronary Sinus (CS). Most of the time operators are concerned about the LV lead placement. However sometimes RV lead which contains ICD coil sometimes poses difficul-

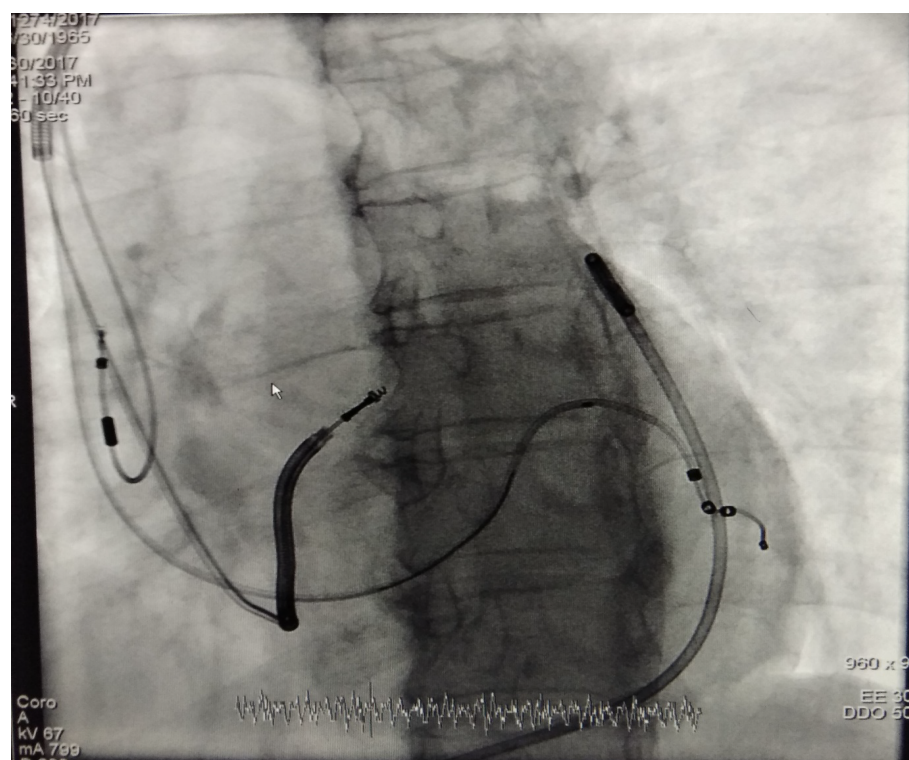


Figure 1: Showing septal CRT-D (RA lead, septal ICD lead and LV lead) in LAO view.

ties to position on the RV apical segment. Improper threshold, loss of trabeculation, dilated RV cavity all are causes for failure to place RV lead in proper position. Septal placement of RV lead is an alternative site in such scenario. It is quite difficult to place such heavy lead in septum. Here I have reported a case where CRT D pacemaker implantation has been done with placement of RV lead in Septal position in a patient of HFrEF with pericardial effusion. Pericardiocentesis was done with placement of pigtail catheter and she was planned for CRT - D placement. Placement of RA and LV lead was done smoothly in this case with a good threshold and impedance. However, ICD lead in RV apical position

could not be done due to smooth RV cavity. Therefore, it was placed in septum and procedure was successful. [Figure 1](#) image, showing all 3 leads in LAO 27-degree position along with pigtail catheter in pericardial space. [Video 1](#) showing synchronised contraction in the LAO 27-degree view. Post implantation QRS was significantly narrow and she was kept on biventricular pacing along with proper medications.

Financial Disclosures

None.

Conflict of Interest

None.