




IMAGE ARTICLE

A Conservative Management of a Duodenal Diverticulitis

Wael Ferjaoui*, Wafa Ghariani, Mohamed Ali Chaouch, Mehdi Khalfallah, Hichem Jerraya and Ramzi Nouira

Department B of Surgery, Charles Nicolle Hospital, Tunis, Tunisia

*Corresponding author: Wael Ferjaoui, Department B of Surgery, Charles Nicolle Hospital, Tunis, Tunisia, Tel: +21652430099



Case Presentation

We present the case of a 78-year-old female patient. Past medical history was unremarkable. She presented with abdominal pain in the epigastric and right upper quadrant region, associated with dyspepsia since 3 months before admission. Physical examination showed tenderness and distension of the abdomen without peritoneal signs. Blood tests showed elevated inflammatory markers (C-reactive protein = 60 mg/l and white blood cell = 19000/mm³). All other blood tests were normal. Radiography of abdomen without preparation revealed some hydroaeric level. A computed tomography of the abdomen showed a voluminous diverticulum of the posterior wall of D2 of 46*10 mm with densification of the mesenteric fat.

A second diverticulum is the anterior wall of D2 of 30*20 mm was also highlighted. The gastro-duodenal transit and the abdominal CT with high opacification confirm the diagnosis by showing several duodenal and jejunal diverticula too. Absolute diet and antibiotic therapy were prescribed. The evolution was favorable (Figure 1).

Duodenal diverticula are rare. Their incidence varies between 2-5% in the general population [1]. Most of those diverticula are asymptomatic and the diagnostic is made by imaging. The treatment in these cases is not necessary. However, many complications can occur such as diverticulitis, gastrointestinal bleeding, perforation and biliopancreatic obstruction. Surgical treatment is indicated in most of these complicated

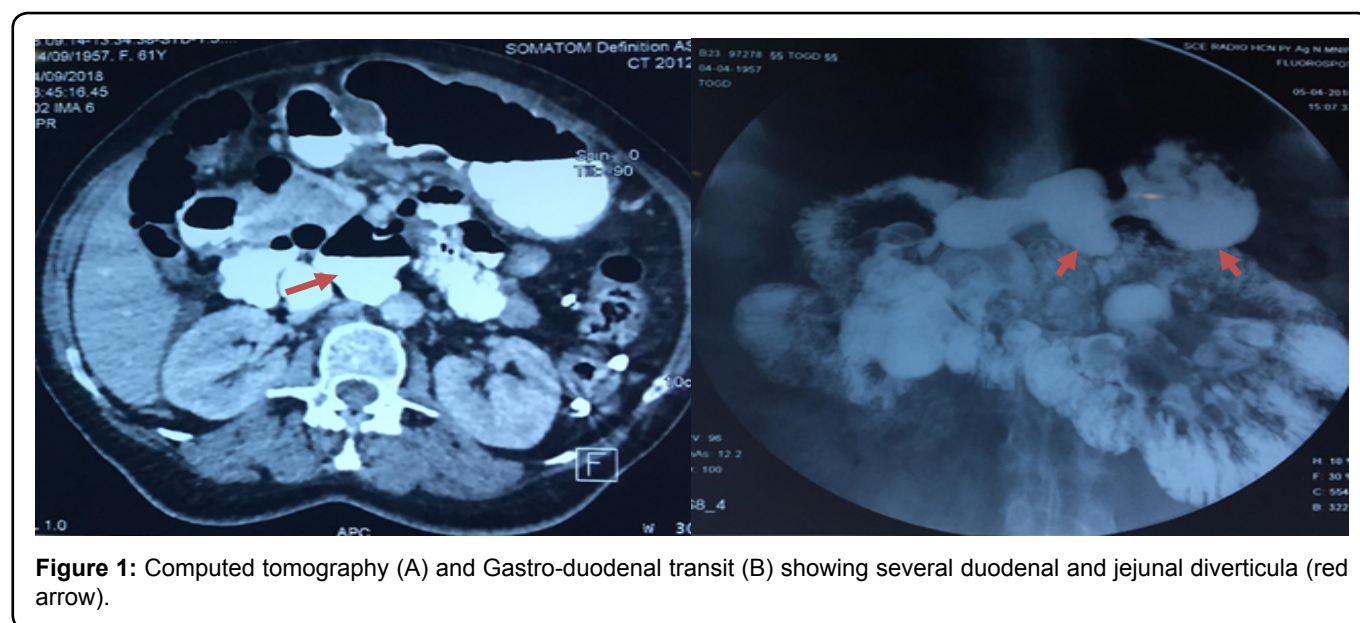


Figure 1: Computed tomography (A) and Gastro-duodenal transit (B) showing several duodenal and jejunal diverticula (red arrow).

cases [2]. We report, herein, a case of a duodenal diverticulitis that we decide to treat it medically. Indeed, and considering the age of the patient we opted for conservative approach. The evolution was favorable.

References

1. Yin WY, Chen HT, Huang SM, Lin HH, Chang TM (2001) Clinical analysis and literature review of massive duodenal diverticular bleeding. *World J Surg* 25: 848-855.
2. Mathis KL, Farley DR (2007) Operative management of symptomatic duodenal diverticula. *Am J Surg* 193: 305-308.