



Image 2:049

Occlusive Intestinal Invagination as First Presentation of Melanoma

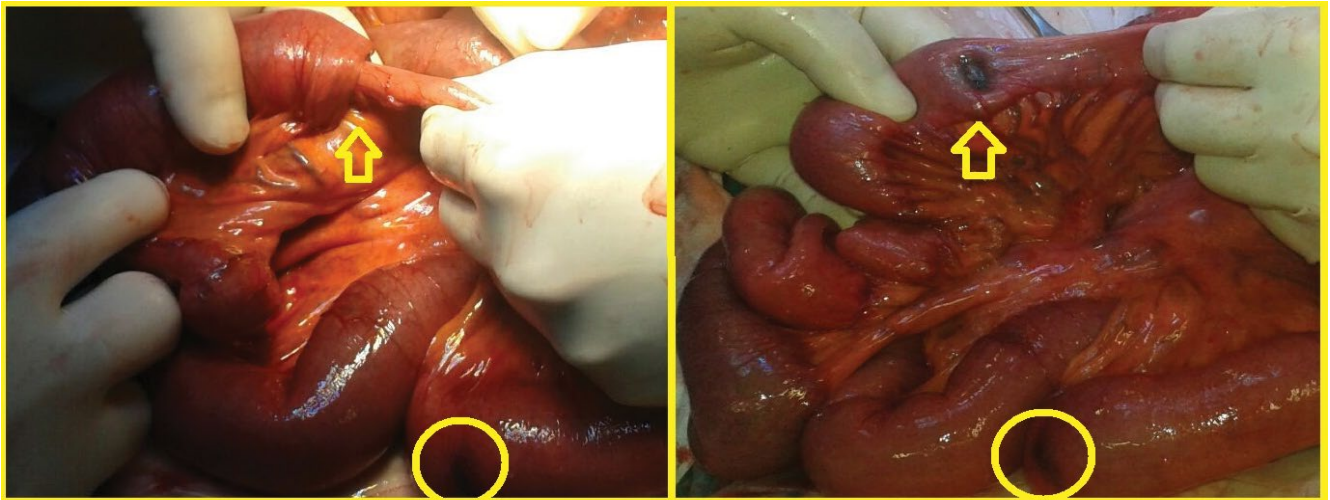


Figure 1: One small bowel invaginations that was reduced manually. A blackish node was found in intussusception.

Abstract

Intestinal metastasis are a common finding in patients affected with melanoma; only exceptionally they can cause enteric intussusceptions and present clinically as bowel obstruction. We present the case of a young woman admitted to our institution for an acute bowel obstruction caused by multiple intestinal invaginations from melanoma metastasis.

Keywords

Melanoma, Ileal melanoma, Ileal intussusceptions, Intestinal occlusion

Text

We present the case of a woman of 38 years with no relevant medical history, except for the removal of two benign epidermal naevi five years earlier, who was admitted to our surgical ward with abdominal pain and vomiting. She underwent abdominal X-Ray and CT-Scan that identified a suspect ileal volvulus. We executed a diagnostic laparoscopy and found one ileocolical invagination that required conversion to laparotomy for the management. We identified multiple blackish nodular lesions of 1-3 cm of size emerging from the serosa through all the length of the jejunum and ileum determining four additional small bowel invaginations that were reduced manually (Figure 1). The ileo-cecal intussusception was instead resected because of signs of ischemia; at the opening of the specimen the serosal nodular lesion was found to have also an intramucosal infiltration (Figure 2). The histological diagnosis was ileal melanoma with BRAF activating mutation and metastasis to the mesenteric lymphnodes. The subsequent stadition through FDG-PET-CT scan revealed multiple metastases in the chest, abdomen, mediastinum and bones; no cutaneous or uveal primitive lesions were found. Postoperative course was uneventful and the patient was referred to oncological treatment with BRAF inhibitors. Intestinal metastasis are a common finding in asymptomatic melanoma patients; only exceptionally they can cause enteric invagination and present clinically as an acute bowel obstruction [1-4].

Information

Enrico Pinotti*, Silvia Frassani, Giulia Lo Bianco, Luca Degrate and Fabrizio Romano
Department of Surgery, San Gerardo Hospital, University of Milano-Bicocca, Italy

*Correspondence: Pinotti Enrico, Department of Surgery, San Gerardo Hospital, University of Milano-Bicocca, via Pergolesi 33, 20900 Monza (MI), Italy, Tel: +390-39233-3651, E-mail: enricopinotti@hotmail.it

Citation: Pinotti E, Frassani S, Bianco GL, Degrate L, Romano F (2016) Intestinal Invagination as First Presentation of Melanoma. Clin Med Img Lib 2:049

Published: July 24, 2016

Copyright: © 2016 Pinotti E, et al. This is an open-access content distributed under the terms of the Creative Commons Attribution License, which permits unrestricted use, distribution, and reproduction in any medium, provided the original author and source are credited.

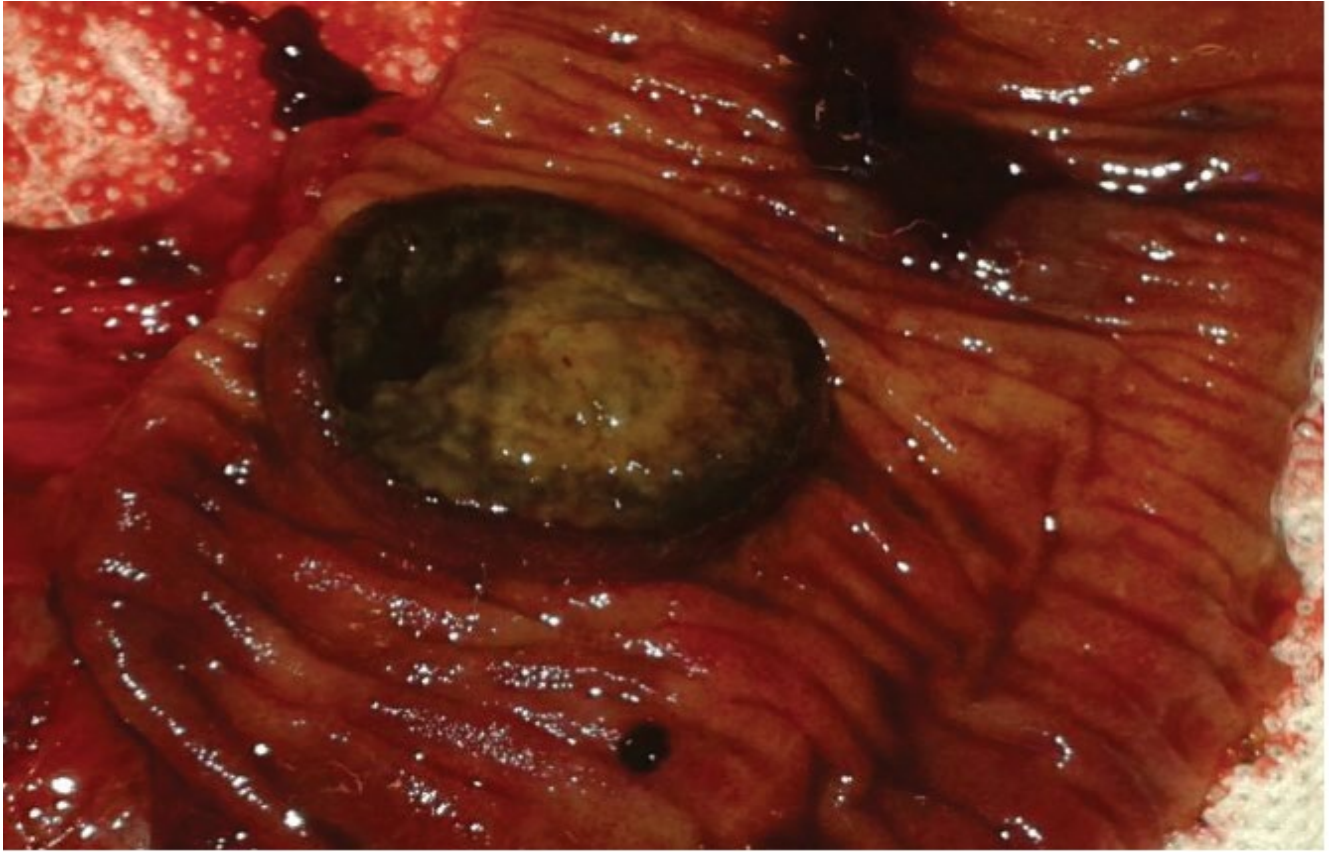

Figure 2: Ileo-cecal intussusception that was resected. Nodular lesion was found to have also an intramucosal infiltration.

Author Contributions

All authors equally contributed to this paper with conception and design of the study, literature review and analysis, drafting and critical revision and editing, and final approval of the final version.

Conflict-of-Interest Statement

No potential conflicts of interest. No financial support.

References

1. Kouladouros K, Gärtner D, Münch S, Paul M, Schön MR (2015) Recurrent intussusception as initial manifestation of primary intestinal melanoma: Case report and literature review. *World J Gastroenterol* 21: 3114-3120.
2. Alvarez FA, Nicolás M, Goransky J, Vaccaro CA, Beskow A, et al. (2011) Ileocolic intussusception due to intestinal metastatic melanoma. Case report and review of the literature. *Int J Surg Case Rep* 2: 118-121.
3. Suzuki S, Watanabe S, Kato H, Hattori H, Morita A Kaohsiung (2012) A case of multiple metastatic malignant melanoma with the largest lesion in the ileum and no skin lesion. *J Med Sci* 28: 683-688.
4. Sundersingh S, Majhi U, Chandrasekar SK, Seshadri RA, Dakshinamurthy SK, et al. (2012) Metastatic malignant melanoma of the small bowel--report of two cases. *J Gastrointest Cancer* 43: 332-335.