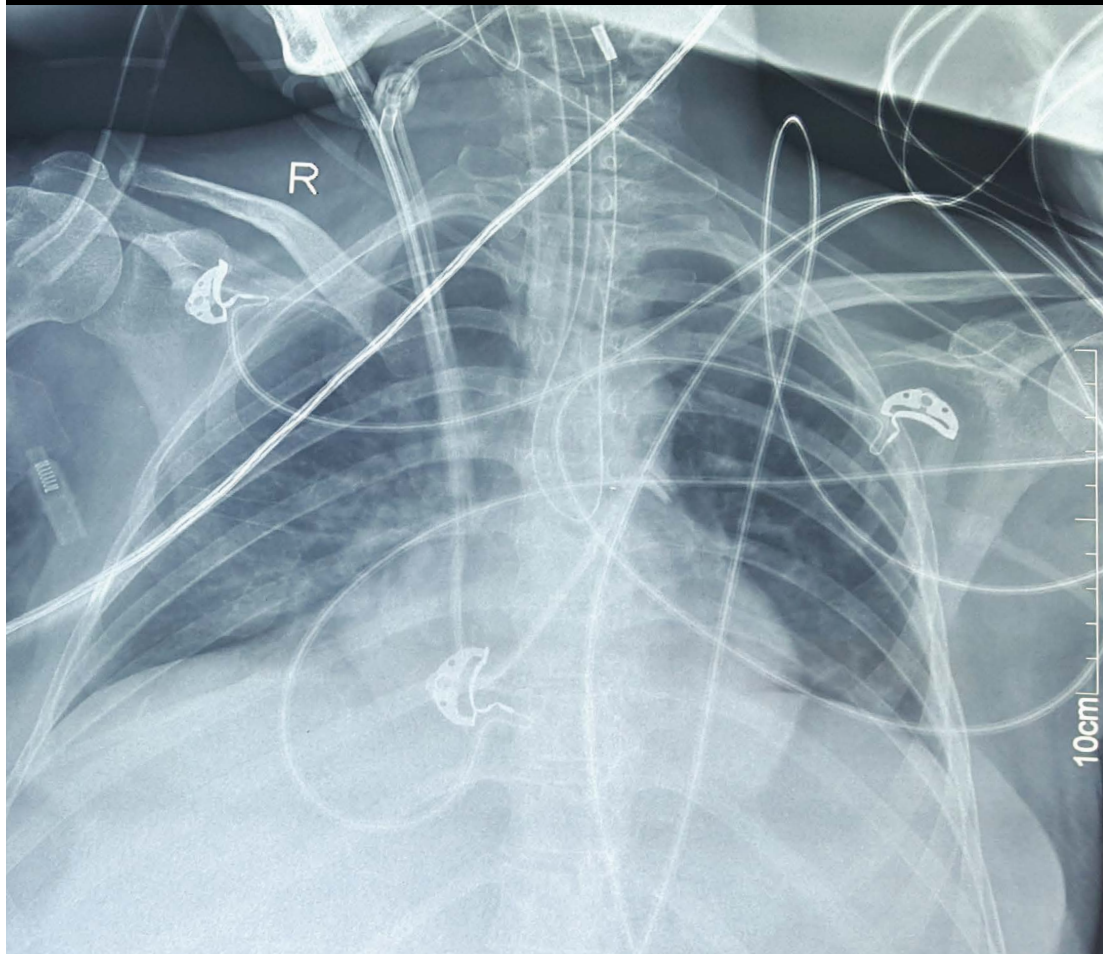




Image 2:021

## Coiled Nasogastric Tube in Oesophagus

RAJNI CR-1528601, M, 000Y  
MOT 4  
23-09-2015, 19:44:18  
W:4096 L:2048



This is a image of an plain X-Ray Chest PA view of a 32 year old female postoperative patient of liver transplant. In this X-ray a nasogastric tube (NG) is seen coiled in the oesophagus which is a rare event. It must be noted that nasogastric tube is coiled as a single U-shaped structure. The tip of NG tube is seen in the upper oesophagus. Normally it gets coiled in the mouth while being inserted through the nose

### Information

**Sameer Sethi\***

Department of Anaesthesia & Intensive Care, Post Graduate Institute of Medical Education and Research, India

\*Correspondence: Sameer Sethi, Associate Professor, Department of Anaesthesia & Intensive Care, Post Graduate Institute of Medical Education and Research (PGIMER), Sector 12, Chandigarh, India, PIN: 160012, Tel: 9317851002, 7087008491, E-Mail: [sameersethi29@gmail.com](mailto:sameersethi29@gmail.com)

**Citation:** Sethi S (2016) Coiled Nasogastric Tube in Oesophagus. Clin Med Img Lib 2:021

**Published:** January 06, 2016

**Copyright:** © 2016 Sethi S. This is an open-access content distributed under the terms of the Creative Commons Attribution License, which permits unrestricted use, distribution, and reproduction in any medium, provided the original author and source are credited.