



CLINICAL IMAGE

Posterior Segment Flail Chest: A Radiological Diagnosis

Yudhyavir Singh^{1*}, Baby Pegu¹ and Kapil Dev Soni²

¹Department of Anesthesiology, Critical Care and Pain Medicine, JPNATC, AIIMS, New Delhi, India

²Critical and Intensive Care, JPNATC, AIIMS, New Delhi, India



*Corresponding author: Dr. Yudhyavir Singh, Associate Professor, Department of Anesthesiology, Critical Care and Pain Medicine, JPNATC, AIIMS, New Delhi, 110029, India, Tel: 9811140057

Description

A 35-year-old male reported to the emergency department after a road traffic accident with complaints of chest pain on the left side and breathing difficulty. On the primary survey, his GCS was full, his airway was patent, breathing spontaneously with a respiratory rate of 28/min with paradoxical movement on the left of the chest, heart rate of 102/min, and blood pressure of 116/78 mmHg. On further evaluation, the chest compression test was positive on the left side, but FAST and eFAST scan were negative. Chest X-ray showed 6th & 7th rib fractures on the left side posteriorly (Figure 1A). CT chest showed two-point fracture (flail segment) of left 6th, 7th & 8th rib posteriorly with displacement, single point fracture of 9th rib left minimal pneumothorax and moderate hemothorax with collapse left lower lobe (Figure 1B). The flail segment was abutting the left hemidiaphragm and mediastinum. Immediately the Intercostal drainage tube was placed on the left side. He required minimum oxygen support with facemask (4 litre/min) and shifted to the trauma intensive care unit

for further management [1-3]. Pain was controlled with paracetamol and fentanyl infusion. For rib fixation of the flail segment, a posterolateral thoracotomy was done (Figure 1C). Intraoperatively, the findings of rib fracture were the same as seen in CT. The erector spinae block was put in for pain relief postoperatively. The indication of rib fixation is a must in ≥ 5 rib flail chest requiring mechanical ventilation or severe displacement found but can be considered in ≥ 3 flail ribs not requiring mechanical ventilation [4]. A posterior flail chest is very rare, indicating high-impact injury. The patient was shifted to the ward on day 2 and was discharged subsequently on day 7 uneventfully.

References

1. Perera TB, King KC (2023) Flail Chest.
2. Dehghan N, de Mestral C, McKee MD, Schemitsch EH, Nathens A (2014) Flail chest injuries: A review of outcomes and treatment practices from the National Trauma Data Bank. *J Trauma Acute Care Surg* 76: 462-468.
3. Alanwer KM, Refat AM, Negm EM (2023) Impact of

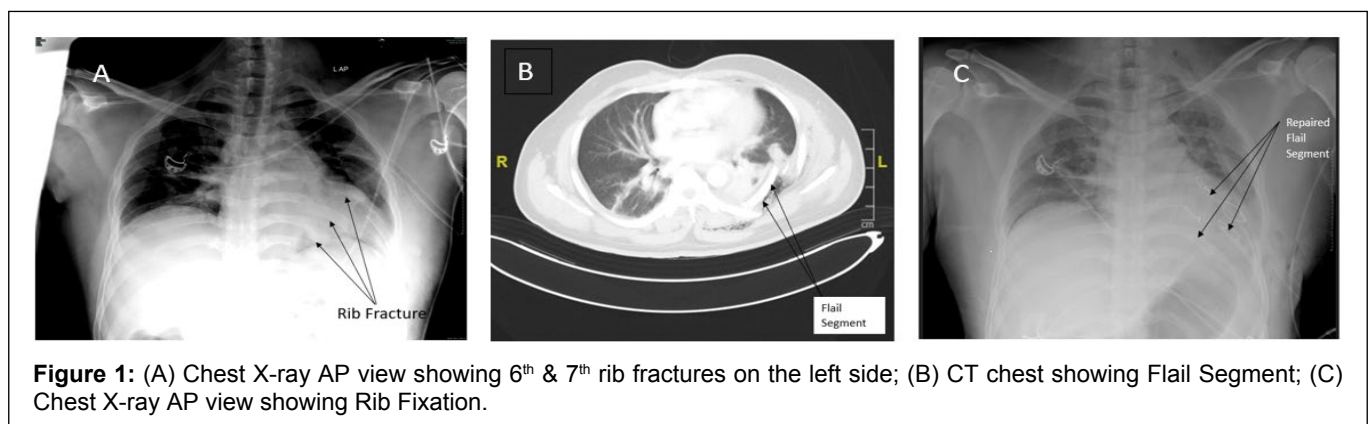


Figure 1: (A) Chest X-ray AP view showing 6th & 7th rib fractures on the left side; (B) CT chest showing Flail Segment; (C) Chest X-ray AP view showing Rib Fixation.

flail chest injury on morbidity and outcome: Ten years' experience at a tertiary care hospital in a developing country. *BMC Anesthesiol* 23: 229.

4. Sawyer E, Wullschleger M, Muller N, Muller M (2022) Surgical rib fixation of multiple rib fractures and flail chest: A systematic review and meta-analysis. *J Surg Res* 276: 221-234.