



Image 1:004

Pulmonary Embolism and Disseminated Intravascular Coagulopathy Associated with Right Atrial Mass

30-year-old man normally fit and healthy presented with collapse and palpitation. He was tachycardic with a heart rate of 120 beats/min and hypoxic with oxygen saturation of 85% on arrival. CT pulmonary angiography confirmed extensive bilateral segmental and sub segmental pulmonary emboli with evidence of right heart strain (Panel A). Laboratory data revealed an elevated international normalized ratio (INR) of 1.4, prolonged partial thromboplastin time (aPTT) of 49 seconds and a low fibrinogen level of 1.0g/L. Blood cultures were unremarkable. CT abdomen and pelvis showed no evidence of malignancy.

3 months prior to this presentation he had a similar coagulopathy with elevated INR of 2.0, a prolonged aPTT of 73 seconds and a low fibrinogen level of <0.3g/L which resolved following administration of fresh frozen plasma and cryoprecipitate. Lupus anticoagulant screen and antinuclear antibodies were normal.

Heparin was administered in view of his coagulopathy. Again, his coagulopathy resolved the following day. Trans oesophageal echocardiography confirmed a large right atrial mass measuring 3.9cm x 1.8cm with a stalk attached near the inferior vena cava (IVC) (Panel B, Online video). There was no obstruction to the tricuspid valve. An urgent operation was performed in view of the risk of further pulmonary embolism. On opening the right atrium a large tumour was found (Panel C) It was attached by a stalk to the eustachian valve and was very close to the IVC cannula. There were no other clots or tumour seen in the right atrium or ventricle. The tricuspid valve appeared normal. No myxomatous tumour was identified on H&E stained sections but only abundant partially organised blood clot with degenerate stroma (Panel D). The patient had an uncomplicated recovery and was discharged home on warfarin 6 days after the surgery. Post-surgery echocardiography confirmed no residual mass in the right atrium and he had no further coagulopathy.

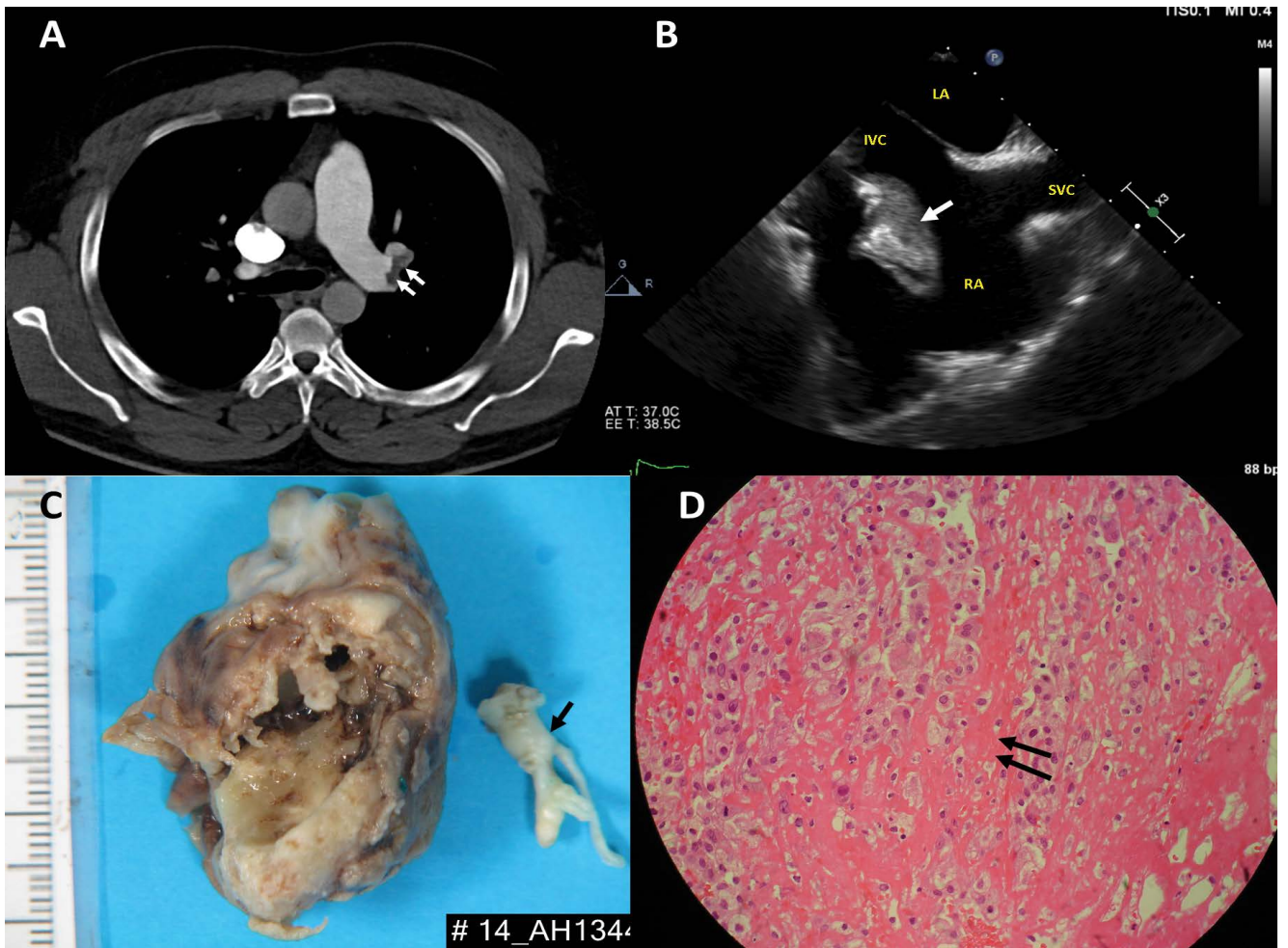
Department of Cardiology, Middlemore Hospital, Auckland, New Zealand

***Corresponding author:** *Jen-Li Looi, Department of Cardiology, Middlemore Hospital, Private Bag 93311, Otahuhu, Auckland, New Zealand, Tel: +649 2760061, Fax: +649 2709746, E-mail: JenLi.Looi@middlemore.co.nz*

Citation: Looi J, Wong S (2015) Pulmonary Embolism and Disseminated Intravascular Coagulopathy Associated with Right Atrial Mass. Clin Med Img Lib 1:004

Published: June 29, 2015

Copyright: © 2015 Looi J. This is an open-access content distributed under the terms of the Creative Commons Attribution License, which permits unrestricted use, distribution, and reproduction in any medium, provided the original author and source are credited.



Panel A: CT pulmonary angiography confirmed extensive bilateral segmental and sub segmental pulmonary emboli (arrows).

Panel B: On the mid-esophagealbicaval view, the right atrial mass (arrow) was seen to attach near the inferior vena cava.

Panel C: The mass was tan and irregular in shape measuring 40mm x 25mm x 24mm. The stalk (black arrow) measured 20mm x 6mm x 4mm. There are areas of haemorrhage and a cystic cavity. There are also calcified areas within the wall of the lesion.

Panel D: There was no myxo matous tumour identified on H&E stained sections. There was abundant partially organised blood clot with degenerate stroma (black arrows).