



A Peculiar Case

Raoul van Vugt* and Peters J

Radboud University Nijmegen Medical Center, The Netherlands

***Corresponding author:** Raoul van Vugt, Radboud University Nijmegen Medical Center, Internal postal code 690, Geert Groote Plein 10, 6500 HB Nijmegen, The Netherlands, Tel: +31 24 3613871, Fax: +31 24 3540501, E-Mail: Raoul.vanvugt@gmail.com

Keywords

Trauma, Head, Knife, CT

A 65-year-old male with a history of an oligodendroglioma (for which debulking surgery in 2012) was presented in our emergency department by ambulance paramedics after he had fallen in his kitchen. Initial examinations revealed an awake, hemodynamically normal patient with a knife penetrating the medial side of his face, just below the right eyeball. Looking at the depth and position of the knife, the assessment was that it was a sharp, pointed knife that went in with a lot of force.

Because of the stable vital parameters we took the time to further investigate the knife's trajectory. A plain X-ray showed the knife's position, outside the neurocranium, with the tip extending just anterior of the first cervical vertebra (Figure 1 and Figure 2). To gain additional information regarding the structures in the face and the exact positioning of the knife a complementary enhanced CT scan with intravenous contrast was made (Figure 3). This scan showed the knife penetrating from the medial side of the orbita, along the

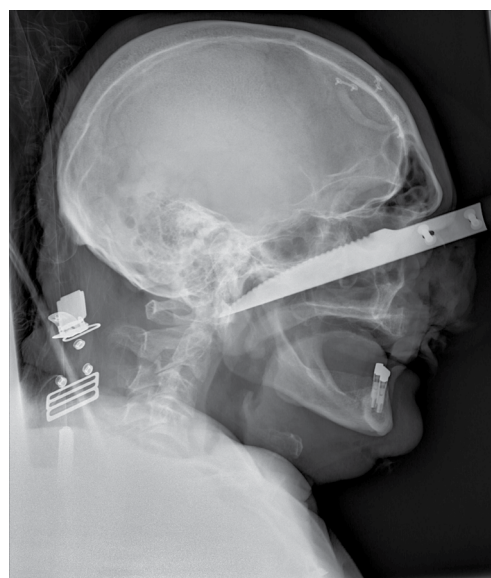

Figure 2: lateral view on X-ray showing a penetrating knife.

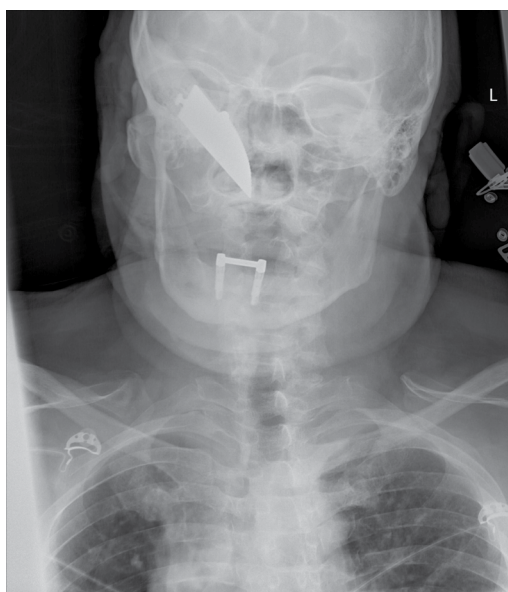


Figure 1: AP view on X-ray showing a penetrating knife.

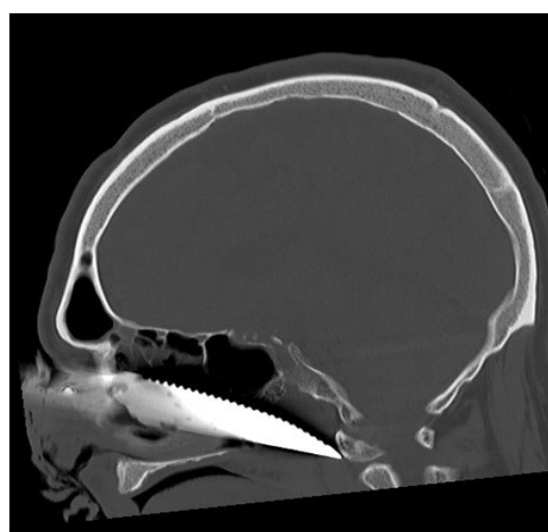

Figure 3: Lateral view on cerebral CT.

maxillary sinus, through the medial pterygoid plate and nasopharynx, ending at the right anterior arch of C1. The eyeball and muscles are untouched, as well is the internal carotid artery.

In the operating theater the knife was removed after admission of antibiotics, after tracheal intubation. No significant bleeding occurred. Through the stab wound some loose bone fragments were seen. This nasal fracture was fixated with two small plates by the craniofacial surgeon. A small tear of the dorsal pharynx was stitched. Postoperatively the patient was extubated on the ICU. The patient

remained stable and could be dismissed from the hospital the day after with oral antibiotics for a week. He recovered this peculiar case uneventfully.

The chance of this patient was that the knife had neither a life-threatening nor a complicating effect on the patient. This condition provided a very useful preparation period to enhance radiological examination and to elaborate the surgery plan as much as possible. Also the emergency team had the opportunity to manage urgent issues and fulfill the requirements of this case.