



## CASE REPORT

# Hypercoagulable State in COVID-19 Severe Symptoms and Non Cardiac T-Wave Inversion: A Case Report

Adipta K\*, Gantira WD, Ari S and Kolanda M

Pondok Gede General Hospital, Indonesia

\*Corresponding author: Adipta K, Pondok Gede General Hospital, Bekasi, West Java, Indonesia



### Abstract

The 2019 novel coronavirus (2019-nCoV) or the severe acute respiratory syndrome corona virus 2 (SARS-CoV-2) as it is now called, is rapidly spreading from its origin in Wuhan City of Hubei Province of China to the rest of the world.

### Keywords

D-dimer, Coagulopathy, T-wave inversion, COVID-19, LMWH

SGOT 34, SGPT 129, Natrium 123, Chlorida 90, D-Dimer 7.852, and Procalcitonin 0.07. ECG revealed T inversion on L I, L II, L III, AVL, V-1, V-3, V-4. Hs-Troponin I result revealed 3.8. Treated with antiplatelet, lisinopril, bisoprolol and combining mechanical ventilator. Also with COVID-19 severe treatment protocols and others such as heparin, acetaminophen, acetylcysteine and curcuma. After 21 days in high care unit miraculously shows good outcome following another x-ray revealed reduce infiltration in both lungs (Figure 1 and Figure 2).

### Case Illustration

A 54-years old male patient came with fever one week, coughing white mucus and difficulty breathing. Thorax x-ray revealed infiltrate perihilar dextra-sinistra and cardiomegaly. Transferred to High Care Unit with SpO<sub>2</sub> 84%, respiratory rate 30/min. His laboratory WBC count 13.620, Limfosit 2, Ureum 55, Creatinine 0.5,

### Discussion

Hypercoagulation of SARS-CoV-2 involves a unique mechanism of thrombo-inflammation triggered by viral infection, originally in the pulmonary vasculature. Interestingly, ECG changes in T-Wave inversion although it is not associated with a troponin elevation. With severe symptoms COVID-19 in these segments

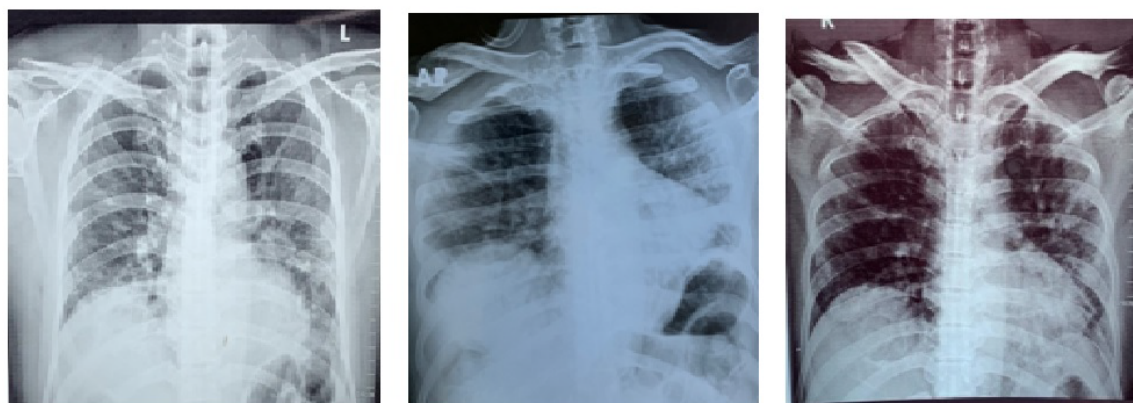
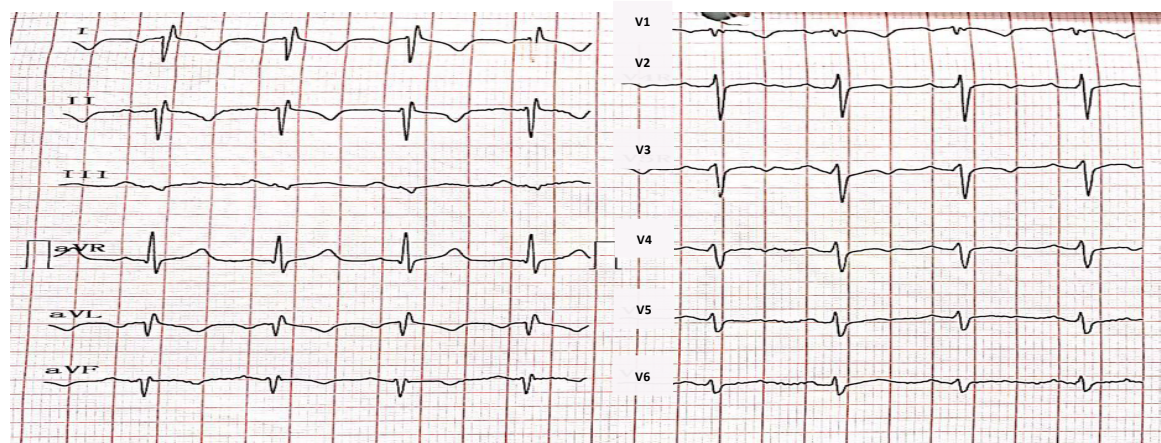


Figure 1: Thorax X-ray results in before transferred to high care unit (HCU) and after 21 days in treatment.



**Figure 2:** ECG result showing T wave inversion.

may be an indicator of the underlying myocardial injury. Numerous studies have explored the benefit of using coagulation inhibitors such as intravenous or subcutaneous low-molecular-weight heparin (LMWH). In this case with intravenous heparin has been doing shows good outcomes and reducing infiltration in both lungs despite been high mortality condition [1-4].

### Conclusion

Hypercoagulable state is challenging clinical problem in the form of venous and arterial thromboembolism, is emerging as one of the most severe sequelae of the disease, and has been prognostic of poorer outcomes. Death might occur due to progressive infection. Appropriate identification of ECG pattern could play an important role in identifying COVID-19 patients at higher risk of adverse events such as intubation and death.

### References

1. Chen Wang, Peter W Horby, Frederick G Hayden, George F Gao (2020) Novel coronavirus outbreak of global health concern. *Lancet* 395: 470-473.
2. Mouhamed Yazan Abou-Ismael, Akiva Diamond, Sargam Kapoor, Yasmin Arafah, Lalitha Nayaka (2020) The hypercoagulable state in COVID-19: Incidence, pathophysiology, and management. *Elsevier* 194: 101-115.
3. Ning Tang, Huan Bai, Xing Chen, Jiale Gong, Dengju Li, et al. (2020) Anticoagulant treatment is associated with decreased mortality in severe coronavirus disease 2019 patients with coagulopathy. *J Thromb Haemost* 18: 1094-1099.
4. Jorge Romero, Isabella Alviz, Michael Parides, Juan Carlos Diaz, David Briceno, et al. (2020) T-wave inversion as a manifestation of COVID-19 infection: A case series. *J Interv Card Electrophysiol* 59: 485-493.