



## CASE REPORT

# The Unusual Occurrence of Leukocytoclastic Vasculitis in Pulmonary Tuberculosis-Case Report

Hingolikar Ankita Prashant<sup>1\*</sup>, Shah Preet Mukesh<sup>2</sup> and Shah Bharat<sup>3</sup>

<sup>1</sup>DNB Resident, Department of General Medicine, Jaslok Hospital & Research Centre, India

<sup>2</sup>ST3 Trainee, Endocrinology & Diabetes, Harrogate District Hospital, UK

<sup>3</sup>Consultant, Department of General Medicine, Jaslok Hospital & Research Centre, India

\*Corresponding author: Dr. Hingolikar Ankita Prashant, DNB Resident, Department of General Medicine, Jaslok Hospital & Research Centre, G Deshmukh Marg, Off Peddar Road, Mumbai, 400026, India, Tel: 9403911039



## Abstract

We present a case of 19 year old girl who presented to us with 4 weeks history of anorexia, weight loss and acute onset (3 days) of papular rashes over both lower extremities and swelling and pain in ankle and knee joints. Broncho-alveolar lavage revealed presence of acid fast bacilli and culture showed growth of mycobacterium tuberculosis. Biopsy of the skin lesion revealed evidence of leukocytoclastic vasculitis with negative immunofluorescence. She responded well to antitubercular therapy with short course of steroids. Tuberculosis related cutaneous leukocytoclastic vasculitis is a rare and our case is unique in manifesting this presentation.

## Keywords

Case report, Vasculitis, Tuberculosis, Immune complex, Corticosteroids, Histopathology

## Introduction

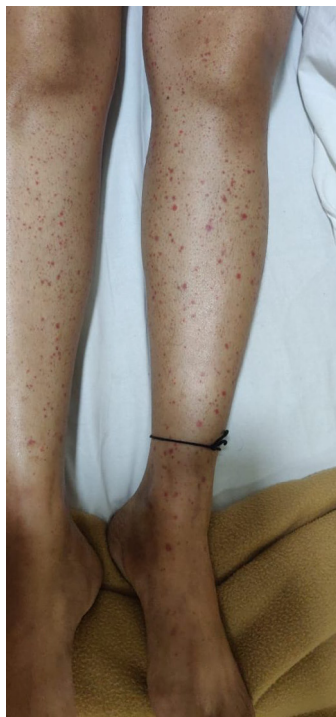Tuberculosis is one of the world's most common communicable diseases.

It is a multisystemic disease with different clinical presentation. Vasculitis has been one of the rare associations. Vasculitis is an inflammation of vessel wall. It affects blood vessels of all sizes and can involve any organ system of the body leading to wide variety of clinical presentation. Etiologic classification of vasculitis include, primary vasculitis (idiopathic) & secondary to autoimmune disease, infections, neoplasm, drug hypersensitivity. It has been classified into Large vessel, medium vessel and small vessel vasculitis based on the

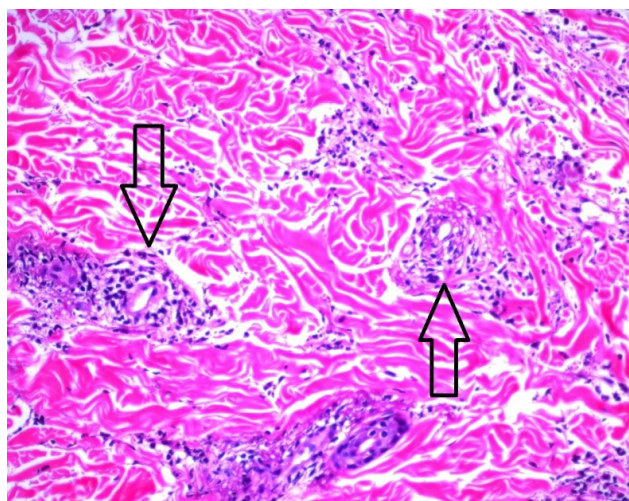
type of vessel involved.

## Case History

A 19-year-old Indian lady, presented with a history of dry cough, anorexia and weight loss of 5 kilograms since the preceding 4 weeks, along with the appearance of a rash on both her legs since the past 3 days. She also complained of pain and swelling of both knees and ankles since the past 3 days. She had similar episodes 3 times in the past 6 months which used to subside temporarily with some medication prescribed by her local physician. (Details of which were not available) No history of fever, sore throat, chest or abdominal pain, blood loss in the stool or urine, menorrhagia, redness of eyes, jaundice or blood transfusion. No history of tuberculosis in the past or contact with any person suffering from tuberculosis. No history of high-risk sexual behavior. No history of regular medications. There was a papular rash over both her legs ([Figure 1](#)) with swelling and tenderness of both her knees and ankles. Her full blood count, renal and liver functions were normal; CRP was 99 mg/dL (normally < 5 mg/dL) and ESR was 60 mm/hour (normally < 20 mm/hour). Immunoglobulin levels were normal. ANA, anti-dsDNA, ENA (Extractable Nuclear Antigen), ANCA, anti-CCP, ASO titre, complement levels, Hepatitis-B and Hepatitis-C serology were negative. Chest X-ray showed bilateral homogenous opacities, thus HRCT of the thorax was done which showed enlarged mediastinal lymph nodes, and multiple nodules in



**Figure 1:** Papular lesions on both the lower limbs.



**Figure 2:** Histopathological examination of the skin biopsy showing areas of fibrinoid necrosis (black arrows) and neutrophilic infiltration of the dermis.

both the upper and lower lobes of the lungs. Bronchoalveolar lavage was done, the sample of which showed acid-fast bacilli on microscopy and the culture sample grew mycobacterium tuberculosis. The skin lesions were biopsied and on histopathological examination, showed areas of fibrinoid necrosis and neutrophilic infiltration of the dermis, with no evidence of the bacilli in the vessel wall (Figure 2). Immunofluorescence didn't reveal deposition of immunoglobulin or complement. This suggested cutaneous leukocytoclastic vasculitis.

She was started on anti-tuberculous therapy and a tapering dose of oral steroids. The rashes and joint symptoms abated after 2 weeks, and her cough and appetite started improving subsequently. Her ESR and CRP simultaneously normalized. No similar episode was noted on follow up.

## Discussion

Cutaneous leukocytoclastic vasculitis is a small vessel vasculitis. It occurs due to deposition of immune complexes in the dermal vessel wall; secondary to infections, malignancies, collagen vascular disorders, or exposure to drugs. Despite tuberculosis being so prevalent in India, leukocytoclastic vasculitis secondary to this infection is very rare, with < 20 cases reported globally [1]. Unlike cutaneous tuberculosis, this condition does not show the presence of the bacilli in the dermal vessel walls [1]. The various proposed mechanisms of pathogenesis are: Direct invasion of the vessel wall, immune complex deposition in the vessel wall, hypersensitivity reaction following the intravascular release of the bacilli, or rifampicin-dependent antibody formation and then immune complex formation [2]. The condition presents as palpable purpuric lesions affecting the lower limbs with/without systemic symptoms. Treatment involves anti-tuberculous therapy and symptomatic treatment of skin lesions [3]. Steroids may be added to aid the recovery of the vasculitic lesions.

## Declaration of Patient Consent

Patient Consent has been obtained.

## Acknowledgement

Nil.

## Financial Support and Sponsorship

This case did not receive any financial support from any source.

## Conflicts of Interest

Authors of this case have no conflict of interests.

## References

1. Meziane M, Amraoui N, Taoufik H, Merniss F (2013) Cutaneous leukocytoclastic vasculitis revealing multifocal tuberculosis. *Int J Mycobacteriol* 2: 230-232.
2. Chan CH, Chong YW, Sun AJ, Hoheisel GB (1990) Cutaneous vasculitis associated with tuberculosis and its treatment. *Tubercle* 71: 297-300.
3. Kim HM, Park YB, Maeng HY, Lee S (2006) Cutaneous leukocytoclastic vasculitis with cervical tuberculous lymphadenitis: A case report and literature review. *Rheumatol Int* 26: 1154-1157.